




Malignant skin tumors:

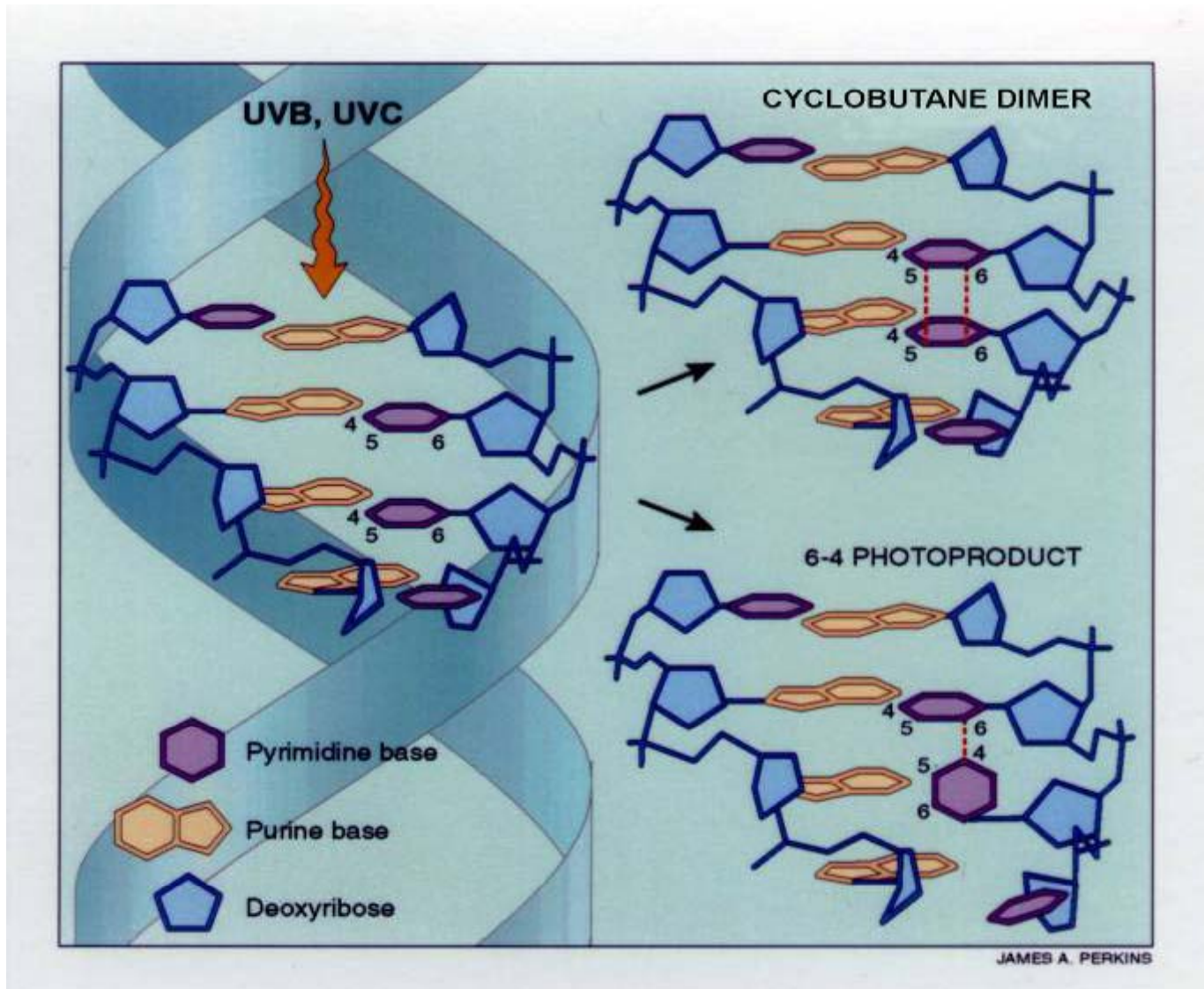
**basal cell cancer, squamous cell cancer,
Kaposi's sarcoma, cutaneous lymphomas**

Diseases

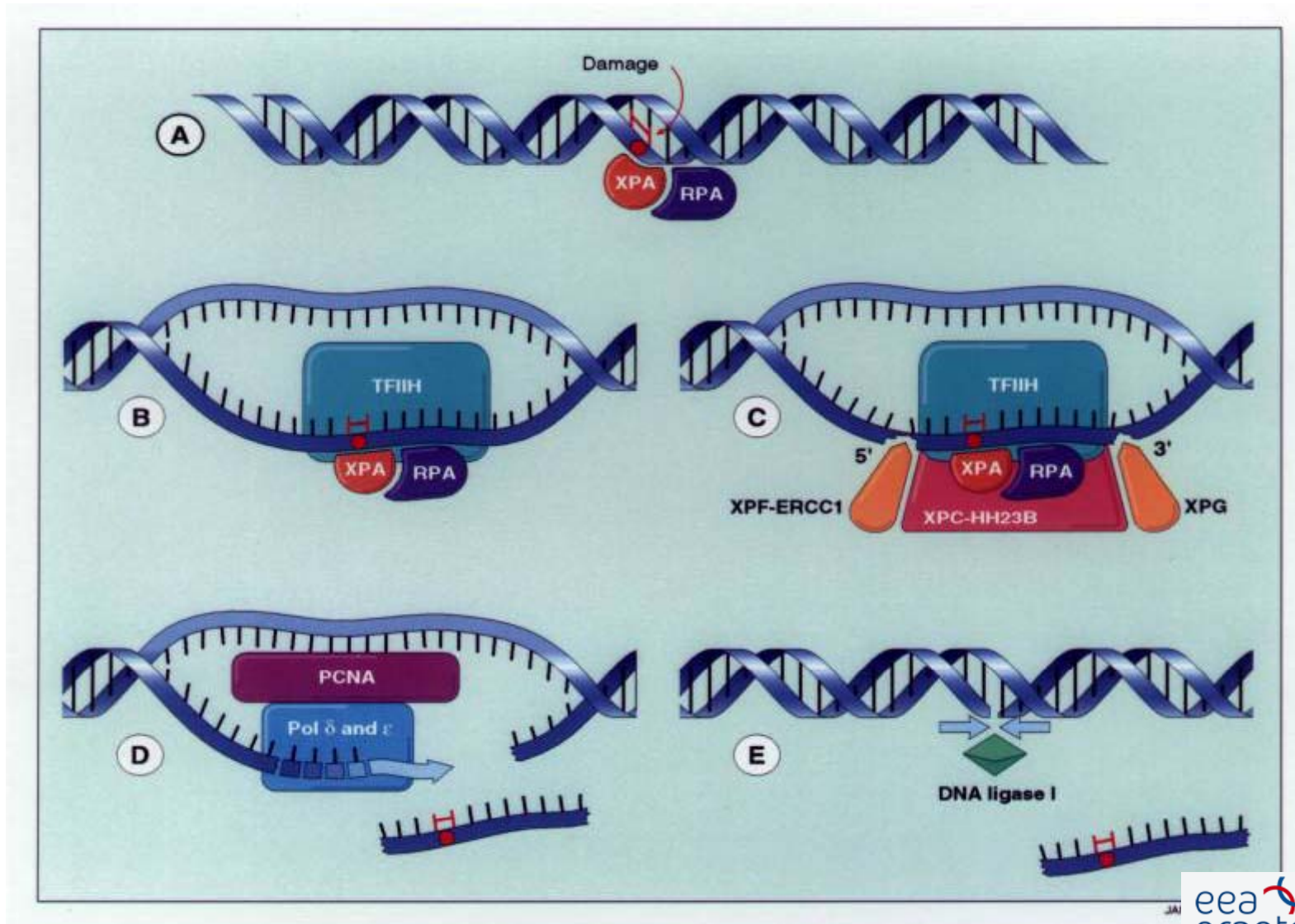
1. Basalioma = basal cell cancer
2. Spinalioma = squamous cell cancer
3. Melanoma malignum = pigment cell cancer



UV photoproducts

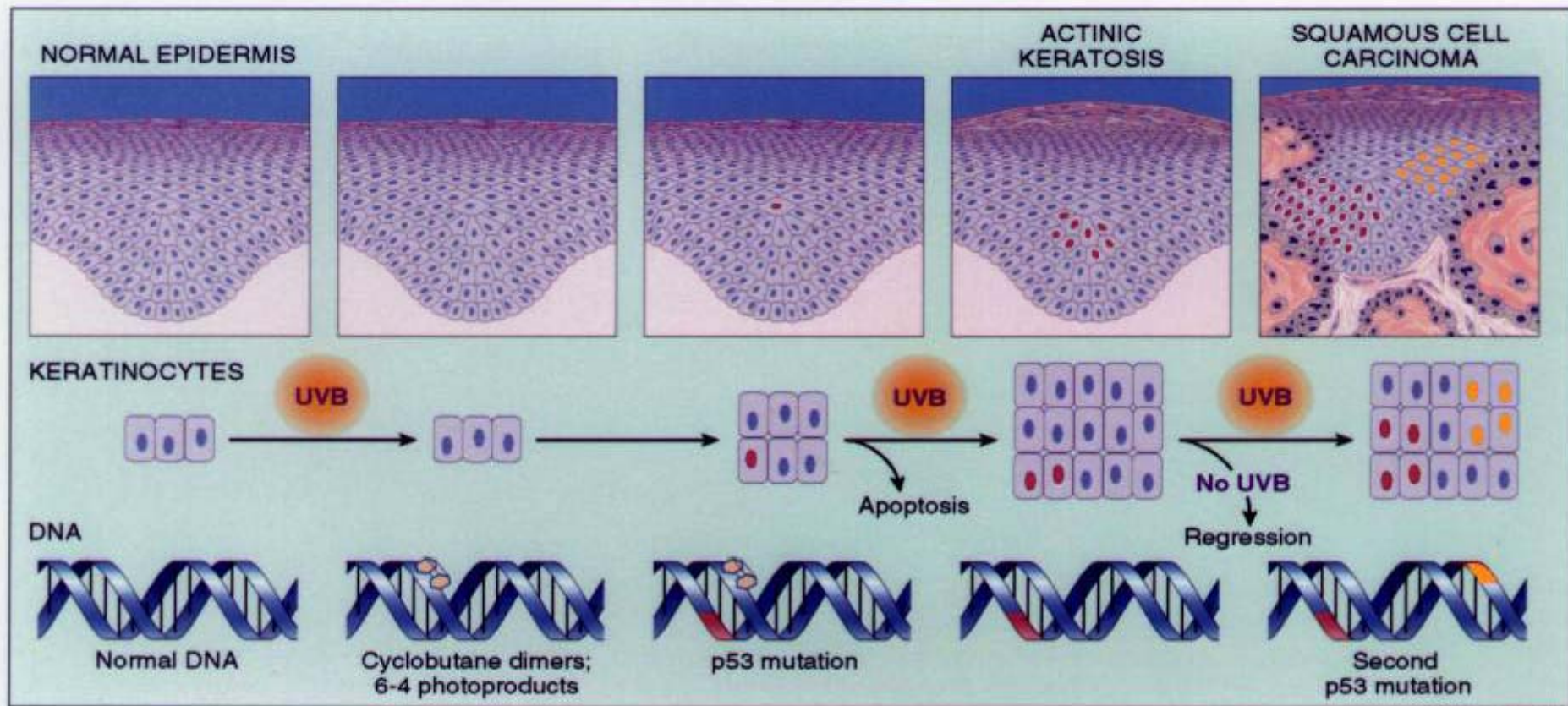


Excision repair



Xeroderma pigmentosum

Clonal development of non-melanoma skin cancer



JAMES A. PERKINS

Basal cell cancer of the skin

History



Krompecher, Ödön
(1870-1926)

Der Basalzellen Krebs
(1903)

Basal cell cancer

BCC types

Multifocal superficial BCC

nodular BCC

subtypes: solid, adenoid, cystic

Infiltrative BCC

subtypes : non-sclerosing, sclerosing, desmoplastic, morphea-like

Fibroepithelial BCC

BCC with appendageal differentiation

subtypes: follicular, eccrin

basosquamous carcinoma

pigmented basalioma

basalcell-naevus syndrome BCC

Mikronodular BCC

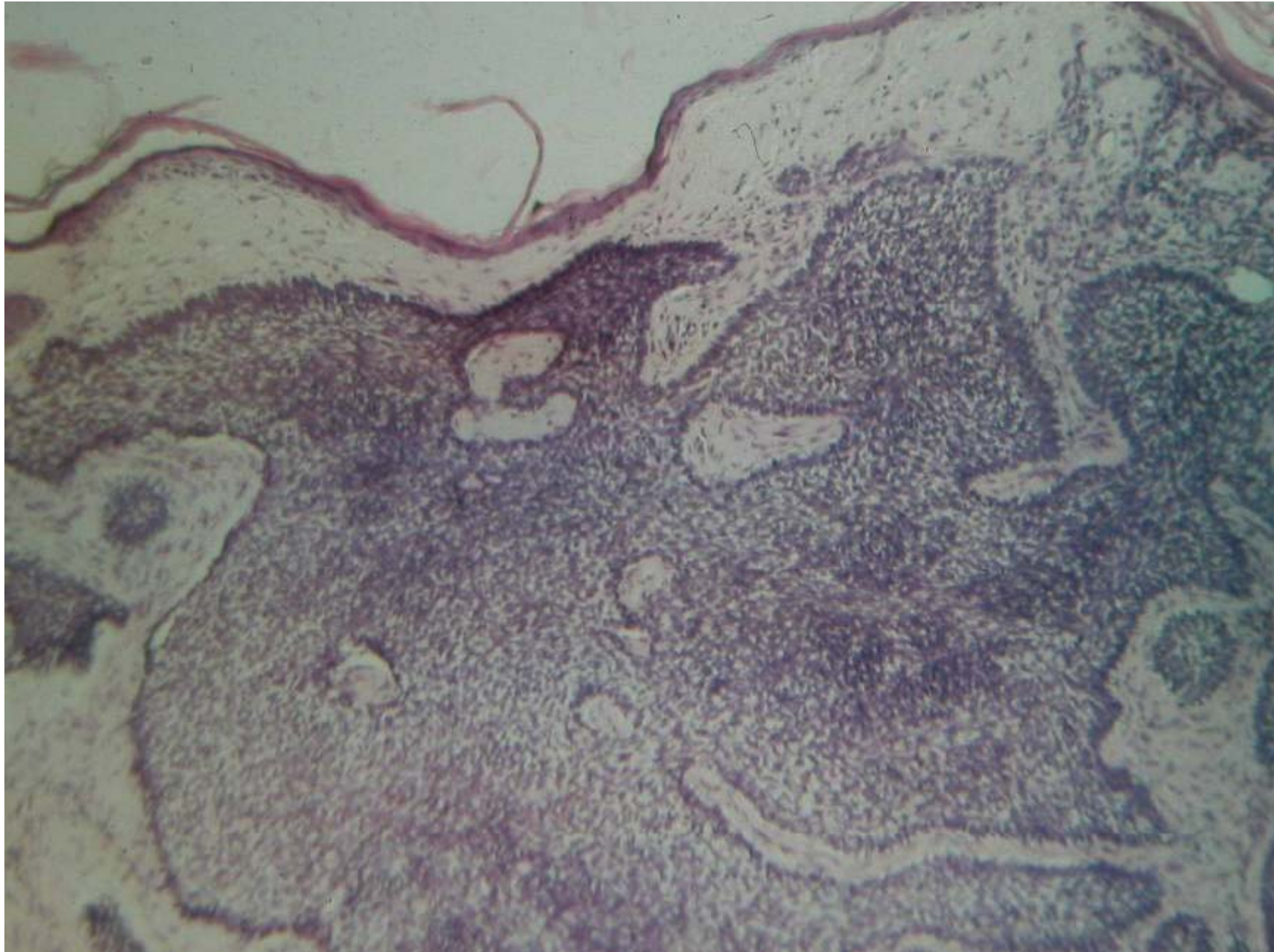
Superficial basal cell cancer

Ulcus rodens

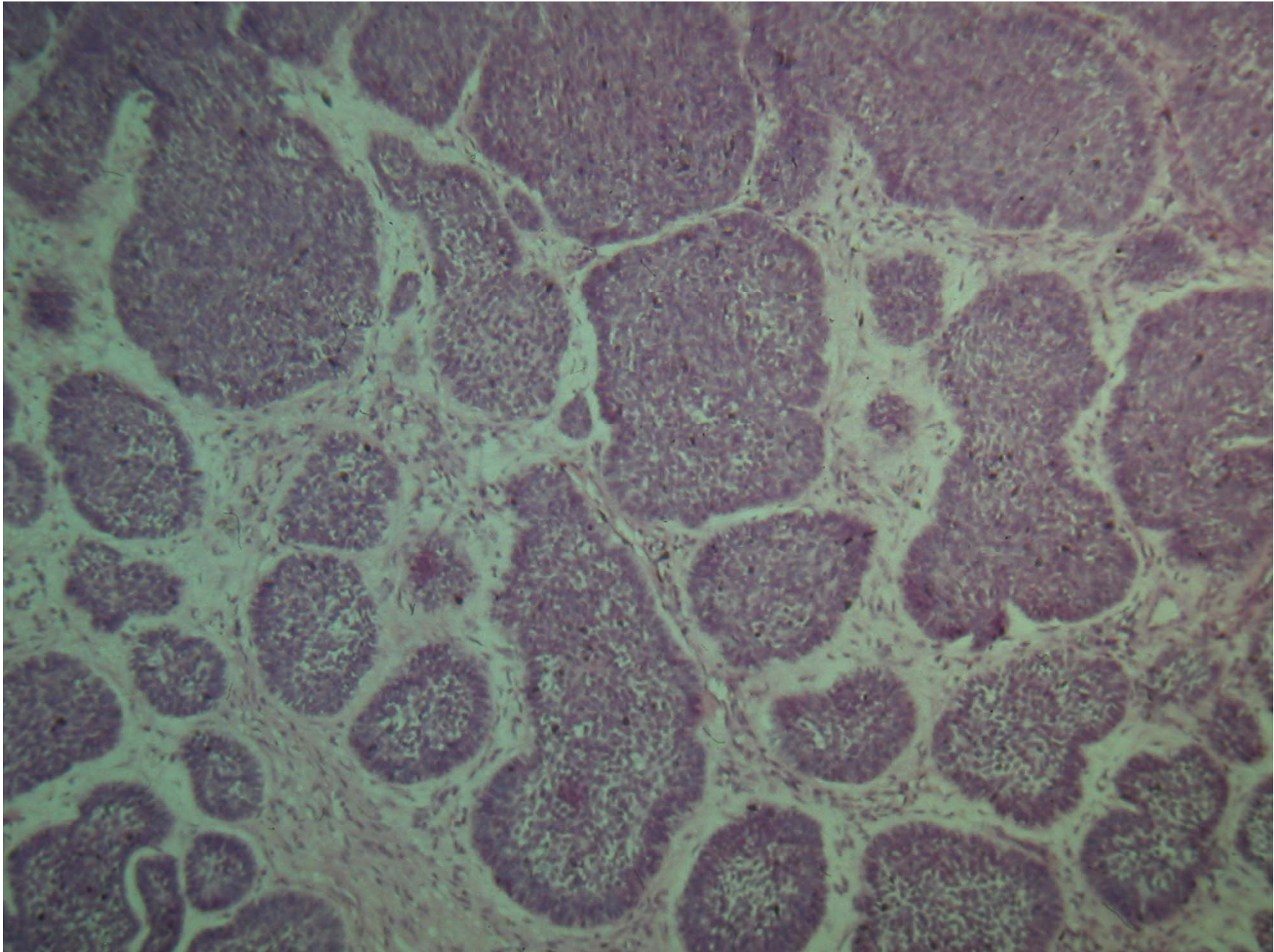
BCC histology types

- Superficial BCC
- Solid BCC
- Pigmented BCC
- Scleroderma- like BCC
- Micronodular BCC
- Infiltrative BCC

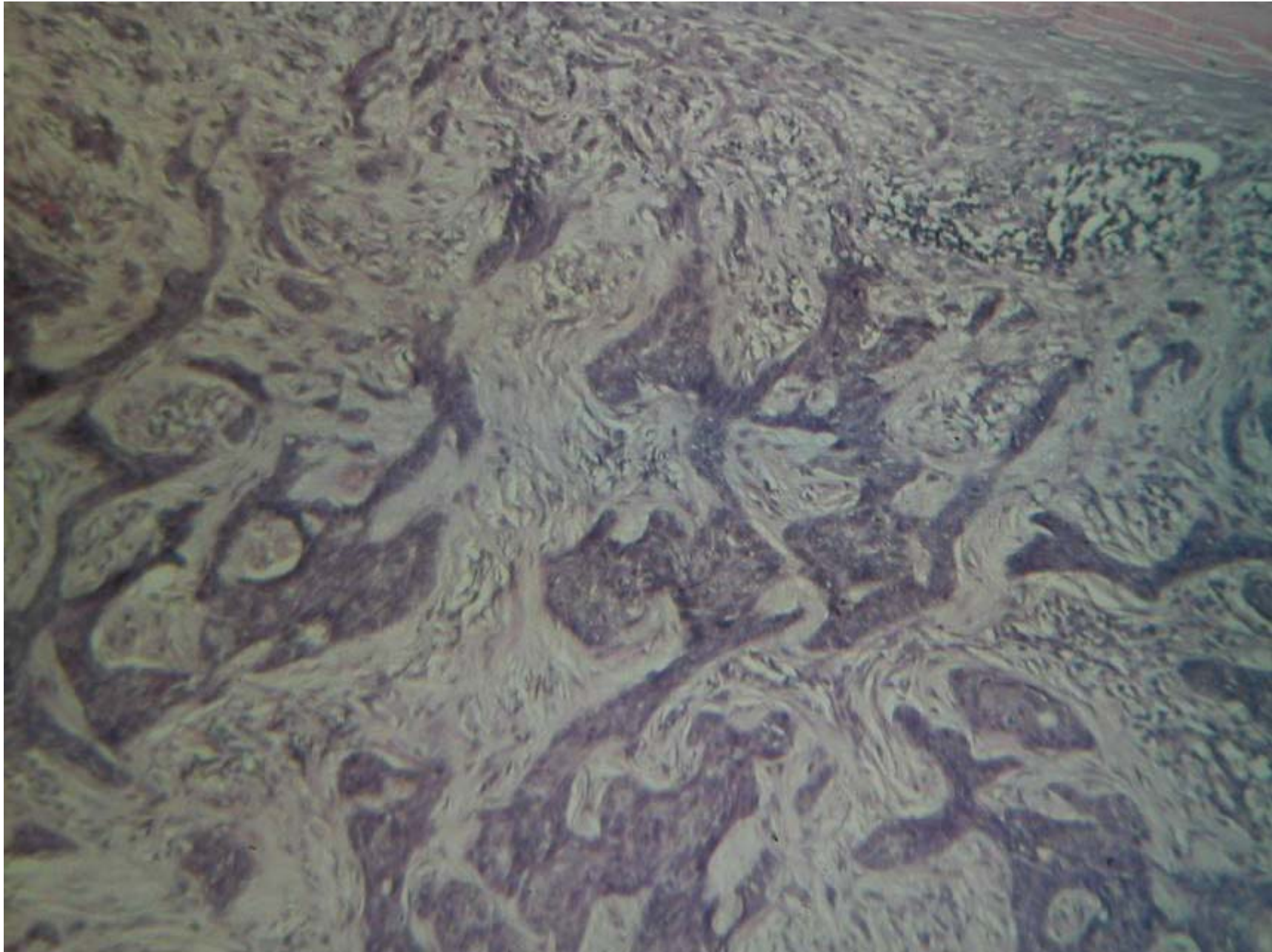
Basalioma solidum



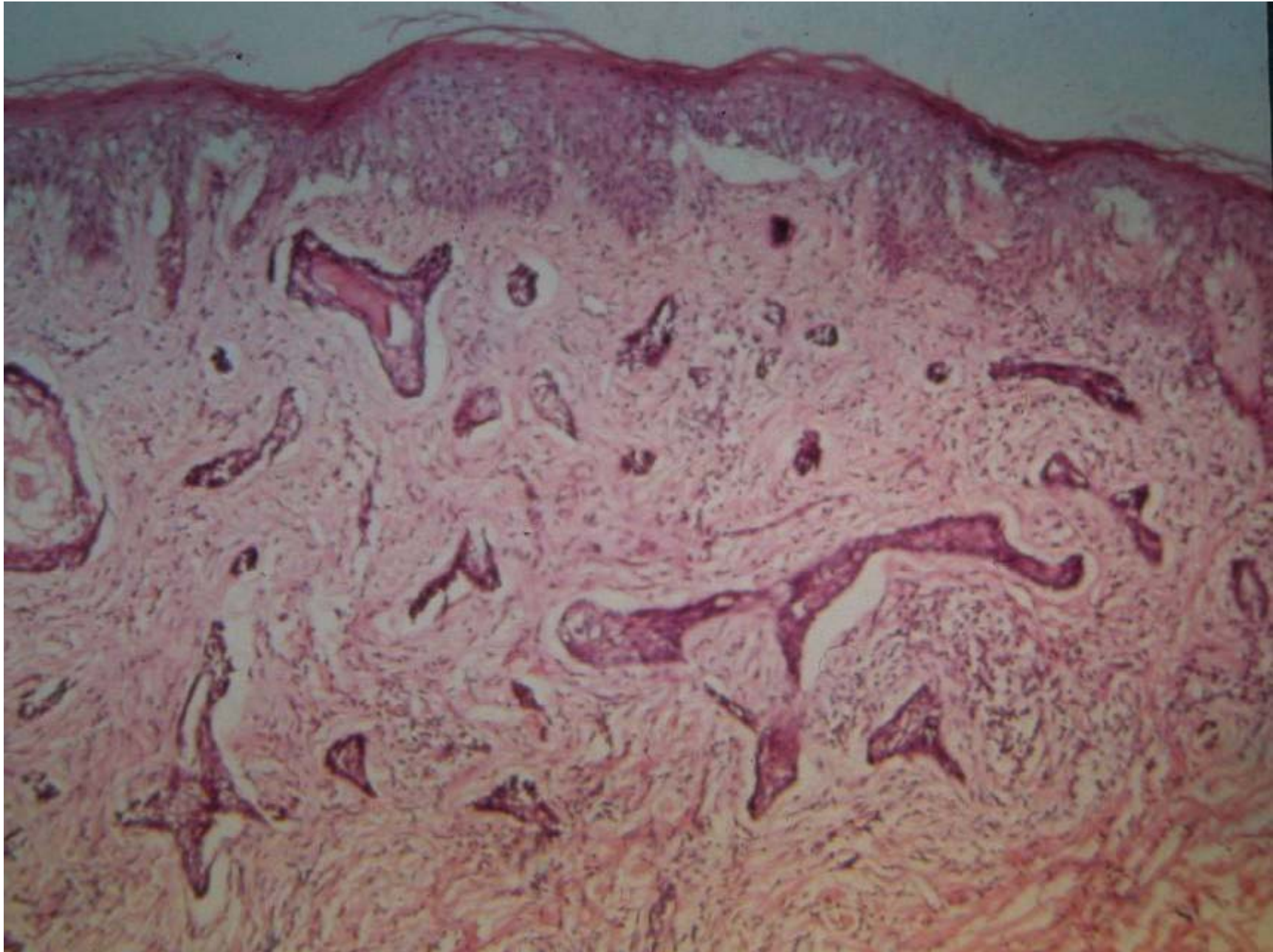
Basalioma micronodularis



Infiltrative basal cell cancer

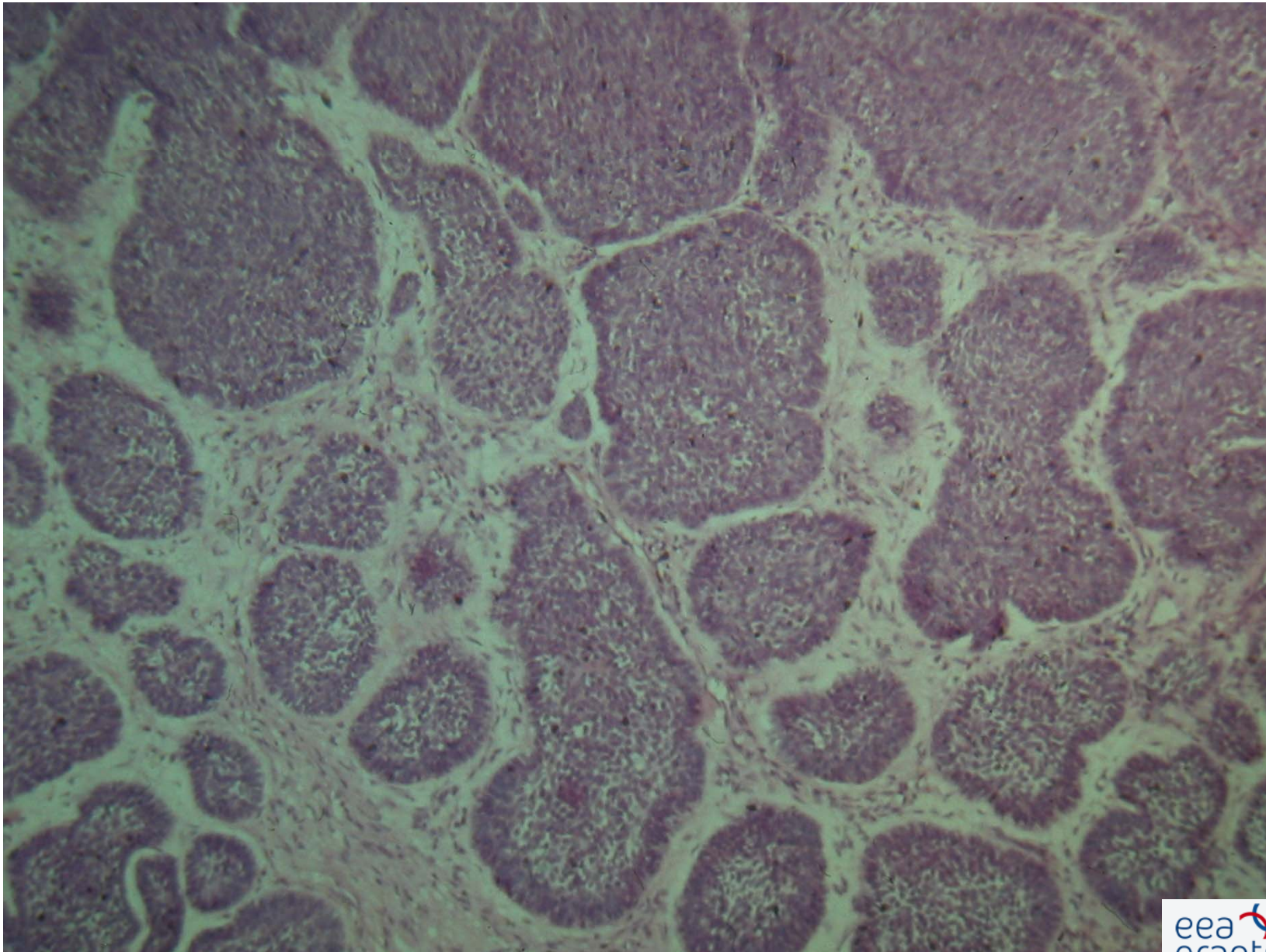


Morphea-like basal cell cc.



Morphea-like

Basalioma adenoides



Basal cell cancer

BCC

Pigmented basal cell cc.

Gorlin-Goltz syndrome

Therapy

Primarily surgical!

Local XRay therapy

MOHS surgery

Cryotherapy

Electrodesiccation and curettage

Photodynamic therapy

Other local therapeutic modalities

Squamous cell cancer

Squamous cell cancer

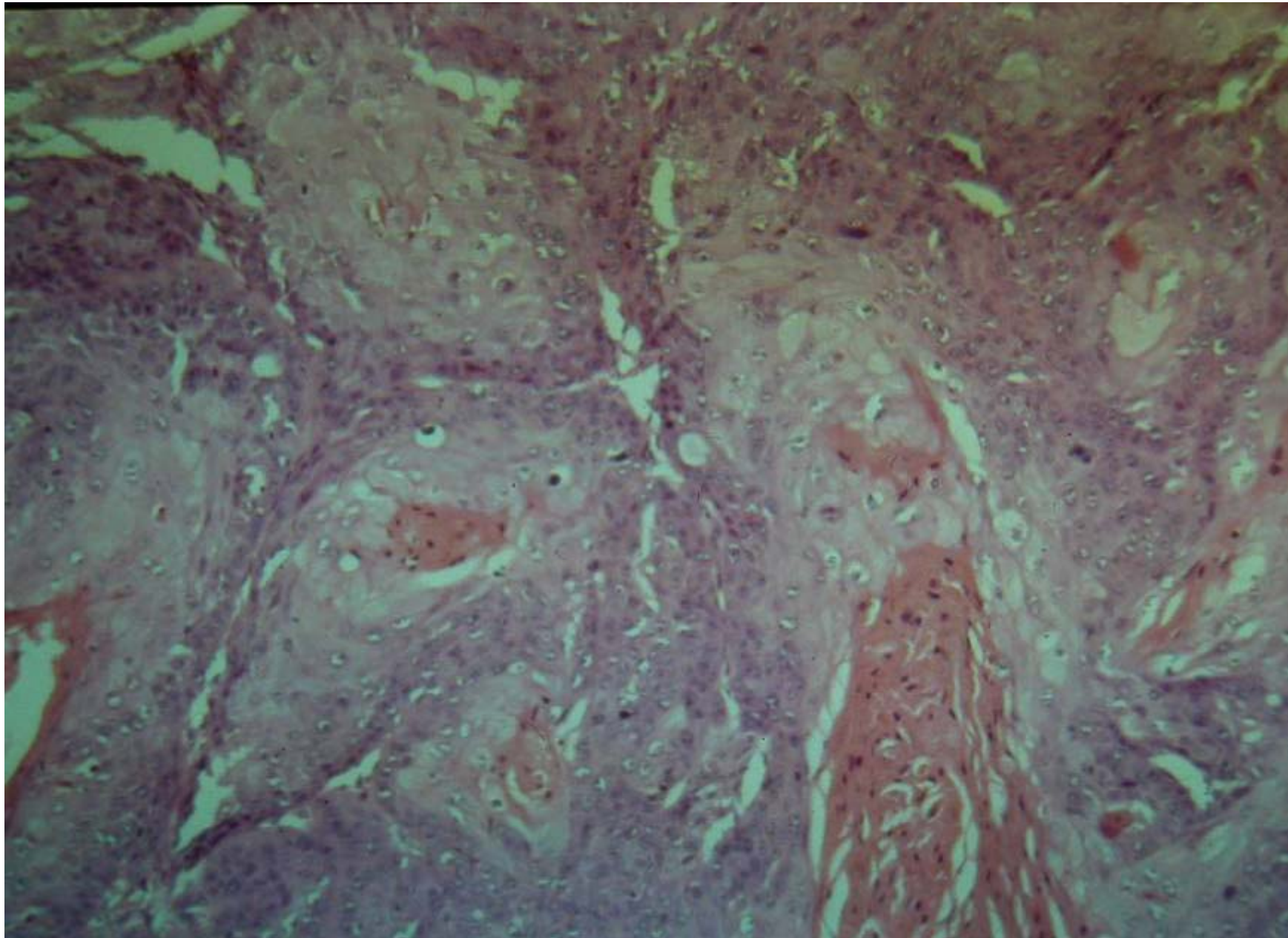
Squamous cell cancer

Lip squamous cell cancer

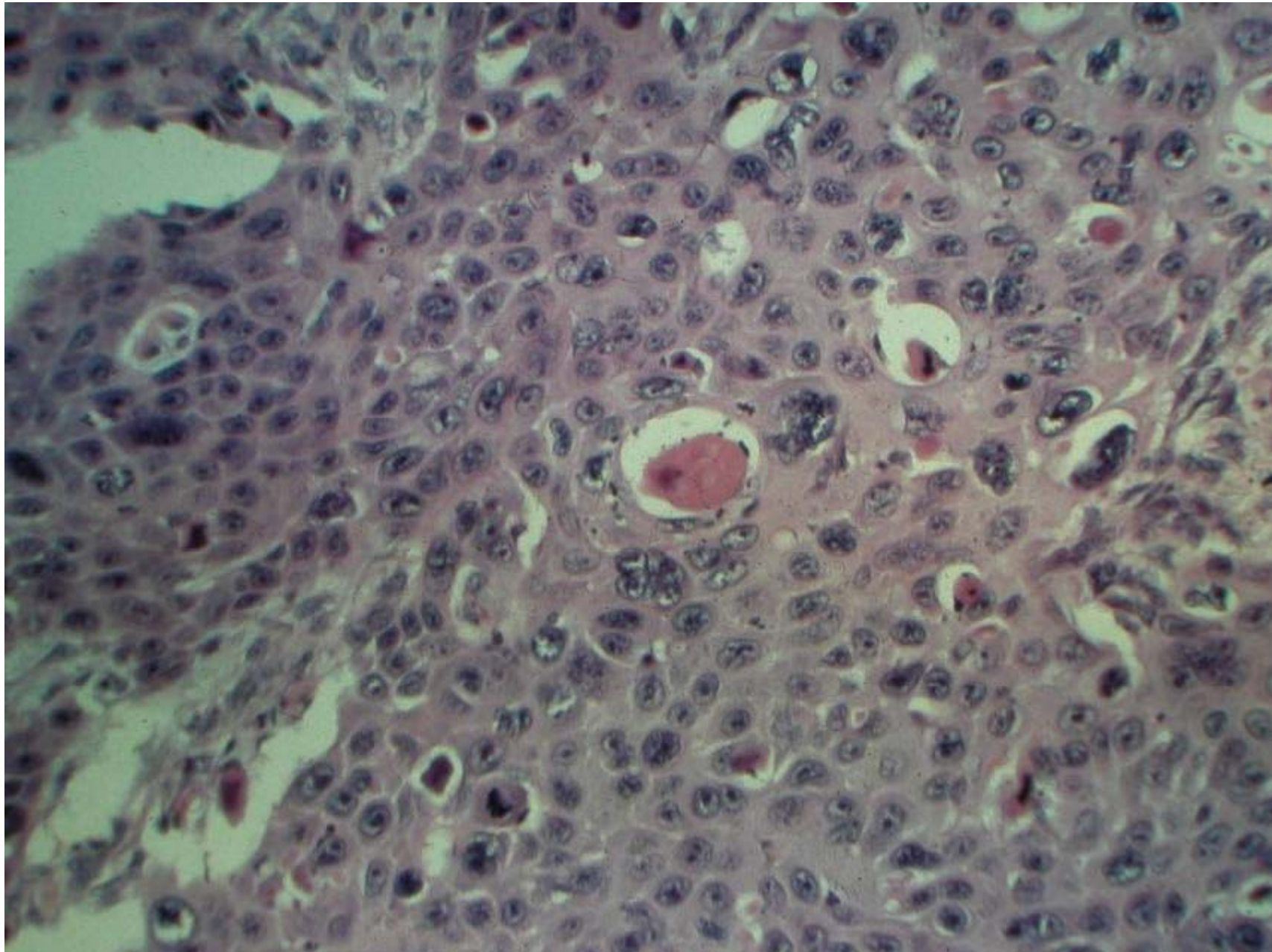
Scar cancer

Carcinoma spinocellulare

Cc. spinocellulare



Cc. spinocellulare



Therapy

Primarily surgical!

Local XRay therapy
MOHS surgery
Photodynamic therapy

Precursors

1. Basal cell cancer = none
2. Squamous cell cancer = Actinic keratoses

Chronic sun damage


Actinic keratosis

Morbus Bowen

Keratoacanthoma

Therapy

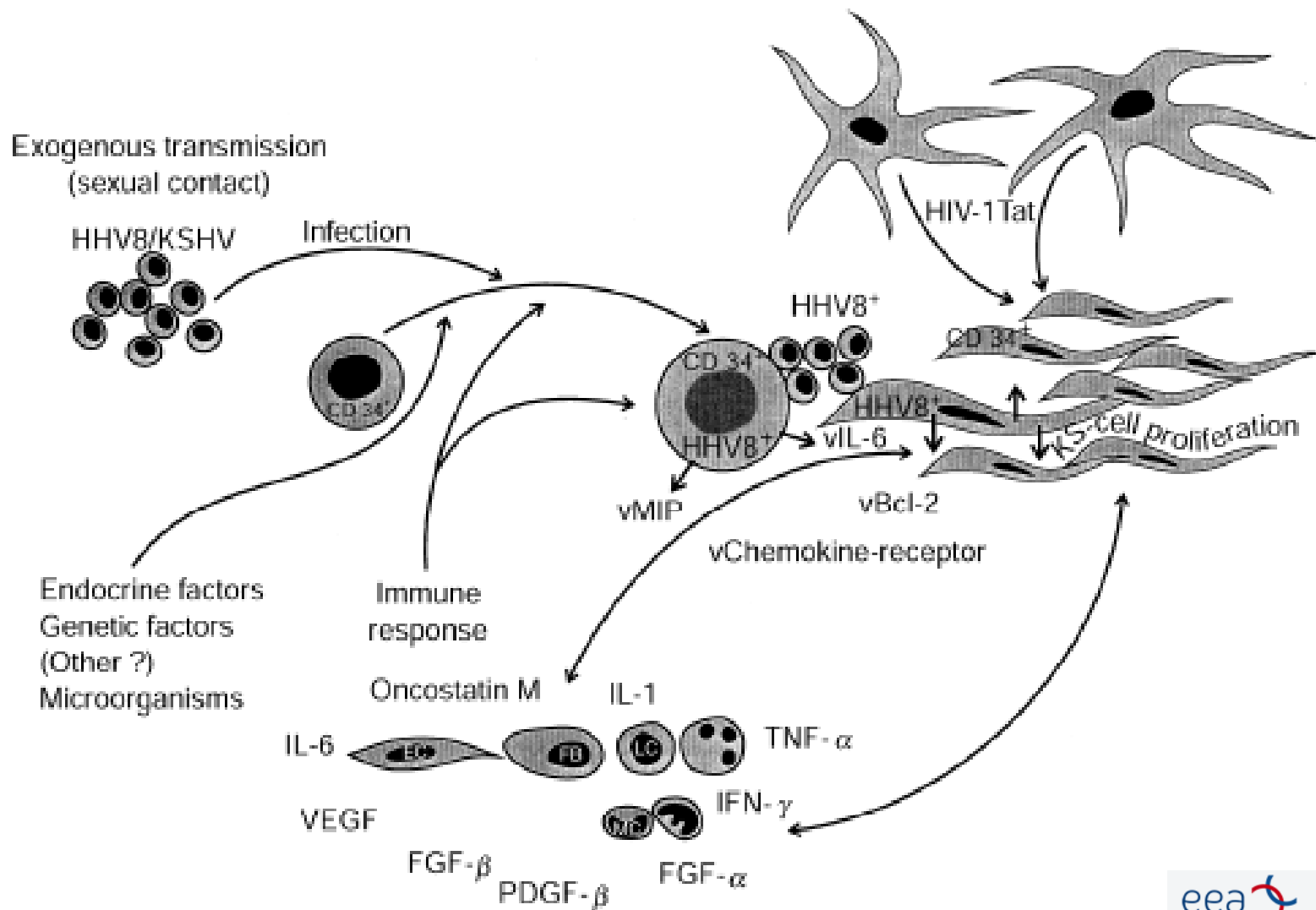
Surgical
Local XRay therapy
MOHS surgery
Cryotherapy
Electrodesiccation and curettage
Photodynamic therapy
Other local therapeutic modalities



Kaposi sarcoma

1. Classic
2. AIDS – related
3. Endemic
4. Iatrogenous

Kaposi sarcoma pathomechanism



Kaposi sarcoma

Kaposi sarcoma

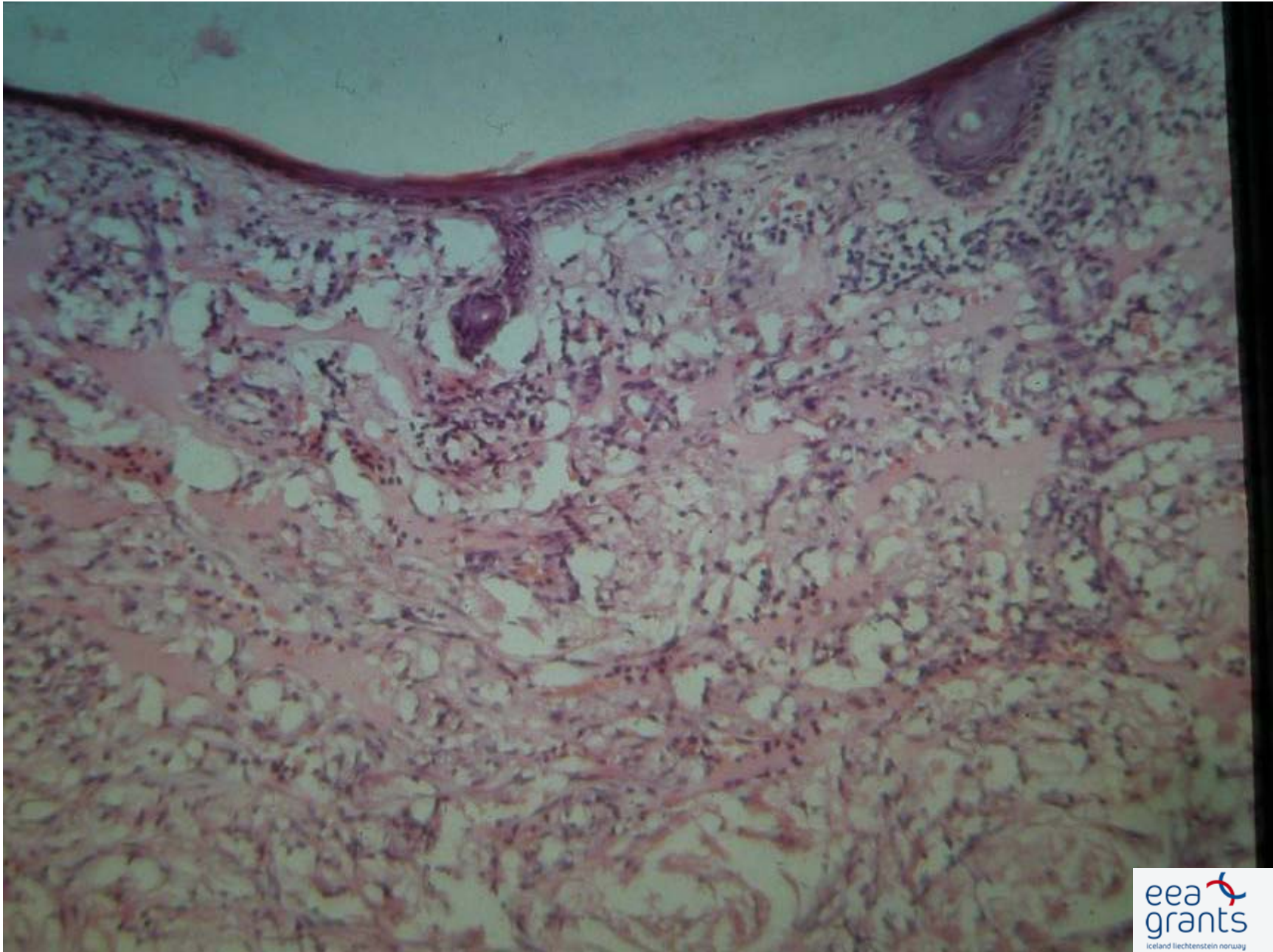
Kaposi sarcoma

Kaposi sarcoma – HIV+ patient

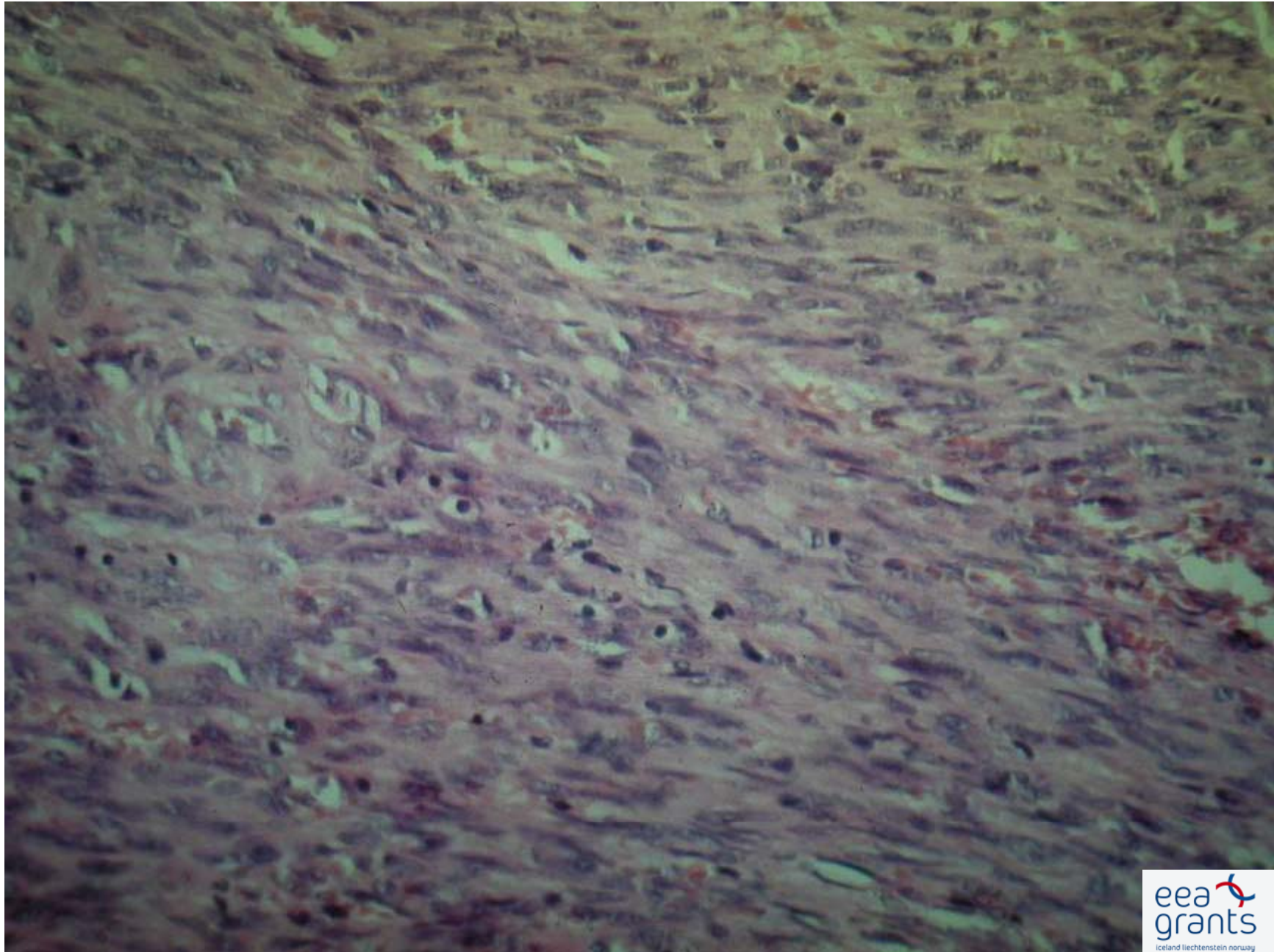
Kaposi mucous membrane localization

Endemic Kaposi sarcoma

Kaposi sarcoma histology



Kaposi sarcoma histology



Therapy

Local XRay therapy
Cryotherapy
Laser coagulation

Interferon alfa-2a
Cytostatic drugs

Lymphomas

Lymphoma classification

CLASSIFICATION FOR PRIMARY CUTANEOUS LYMPHOMAS

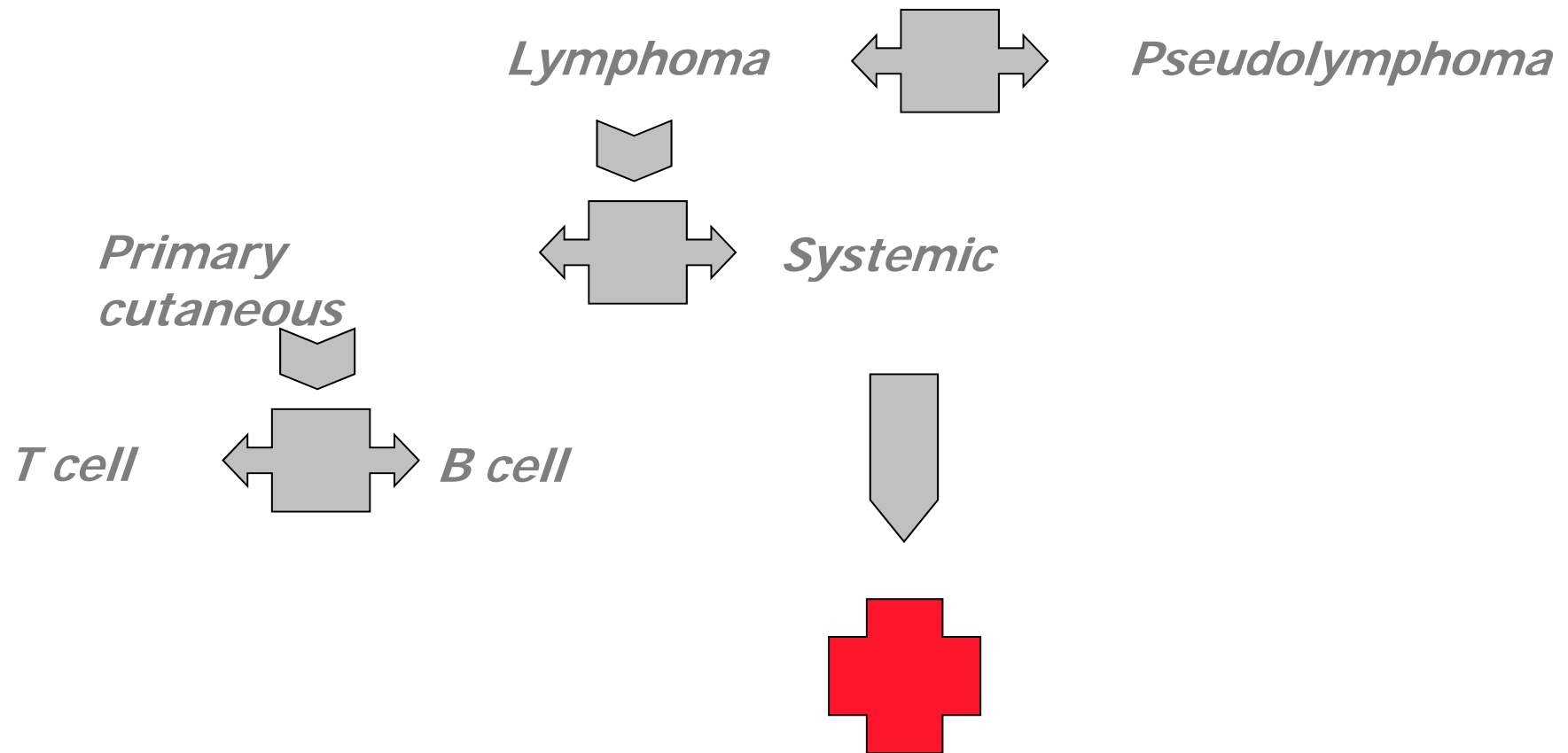
Table 1. EORTC Classification for Primary Cutaneous Lymphomas

Primary CTCL	Primary CBCL
Indolent	Indolent
MF	Follicle center cell lymphoma
MF + follicular mucinosis	
Pagetoid reticulosis	Immunocytoma (marginal zone B-cell lymphoma)
Large cell CTCL, CD30 ⁺	
Anaplastic,	
Immunoblastic	
Pleomorphic	Intermediate
Lymphomatoid papulosis	Large B-cell lymphoma of the leg
Aggressive	
SS	
Large cell CTCL, CD30 ⁻	
Immunoblastic,	
Pleomorphic	
Provisional	Provisional
Granulomatous slack skin	Intravascular large B-cell lymphoma
	Plasmacytoma
CTCL, pleomorphic small/medium-sized	
Subcutaneous panniculitis-like T-cell lymphoma	

Abbreviations: CTCL, cutaneous T-cell lymphoma; CBCL, cutaneous B-cell lymphoma; MF, mycosis fungoides; SS, Sezary syndrome.



Lymphoma diagnosis





Cutan lymphoma staging

- *Clinical picture*

- *Histology*

- *Immunohistochemistry*

- *Gene rearrangement*

Periferal blood (Sézary cell, flow cytometry, gene rearrangement)

Bone marrow

Lymph node

Internal organs: XRay, Echo, CT

Lymphoma classification

CLASSIFICATION FOR PRIMARY CUTANEOUS LYMPHOMAS

Table 1. EORTC Classification for Primary Cutaneous Lymphomas

Primary CTCL	
Indolent	
MF	
MF + follicular mucinosis	
Pagetoid reticulosis	
Large cell CTCL, CD30 ⁺	
Anaplastic,	
Immunoblastic	
Pleomorphic	
Lymphomatoid papulosis	
Aggressive	
SS	
Large cell CTCL, CD30 ⁻	
Immunoblastic,	
Pleomorphic	
Provisional	
Granulomatous slack skin	
CTCL, pleomorphic small/ medium-sized	
Subcutaneous panniculitis-like T-cell lymphoma	

Abbreviations: CTCL, cutaneous T-cell lymphoma; CBCL, cutaneous B-cell lymphoma; MF, mycosis fungoides; SS, Sezary syndrome.

Primary cutaneous T cell lymphoma

Mycosis fungoides

- Premycotic stage
- Plaque stage
- Tumor stage

Sézary syndrome

Mycosis fungoides

Mycosis fungoides premycotic stage

Mycosis fungoides premycotic stage

MF plaque stage

MF tumor stage

MF tumor stage

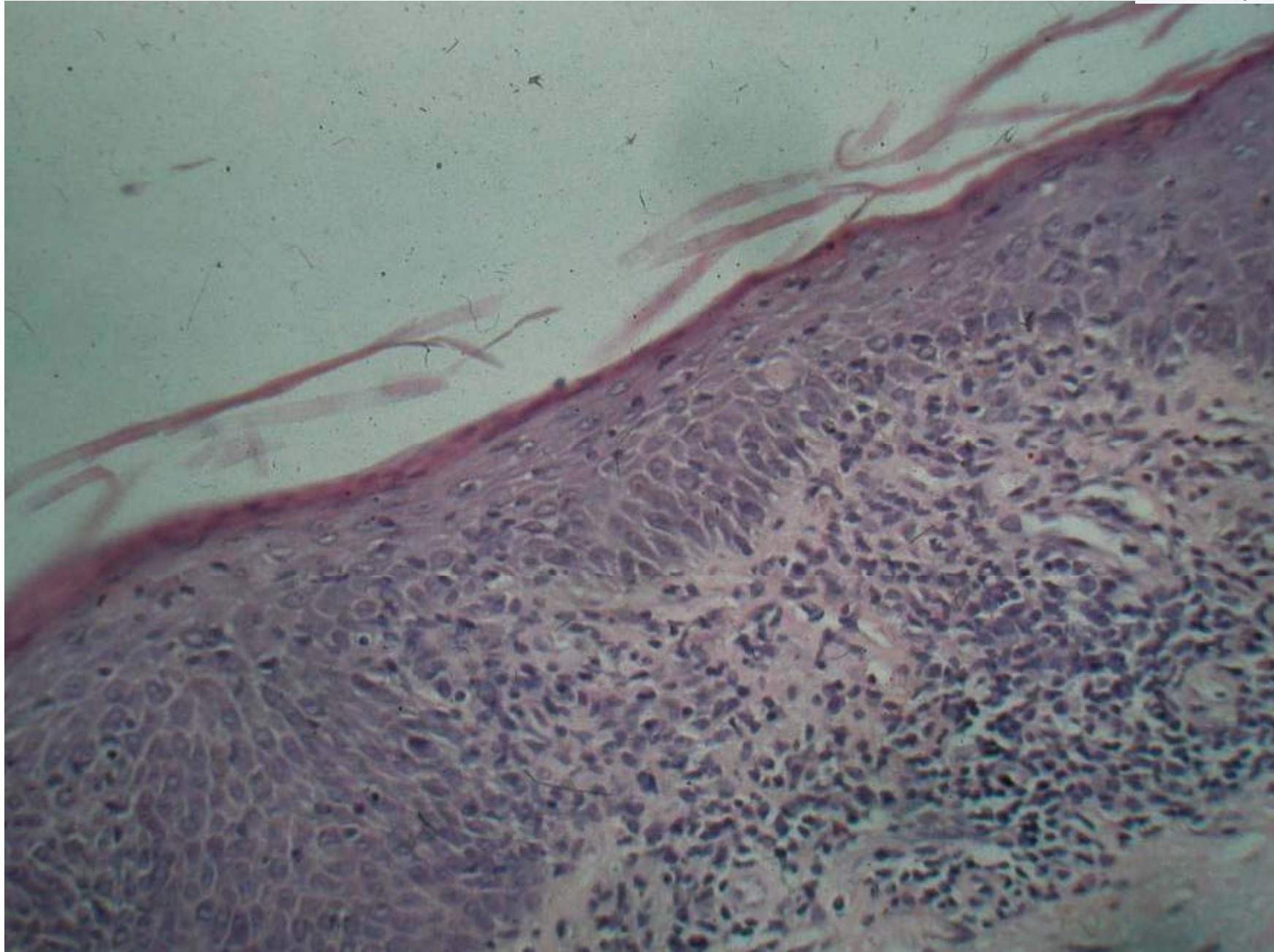
CD 30 positive lymphoma

Sézary syndrome

Sezary syndrome

Sezary syndrome

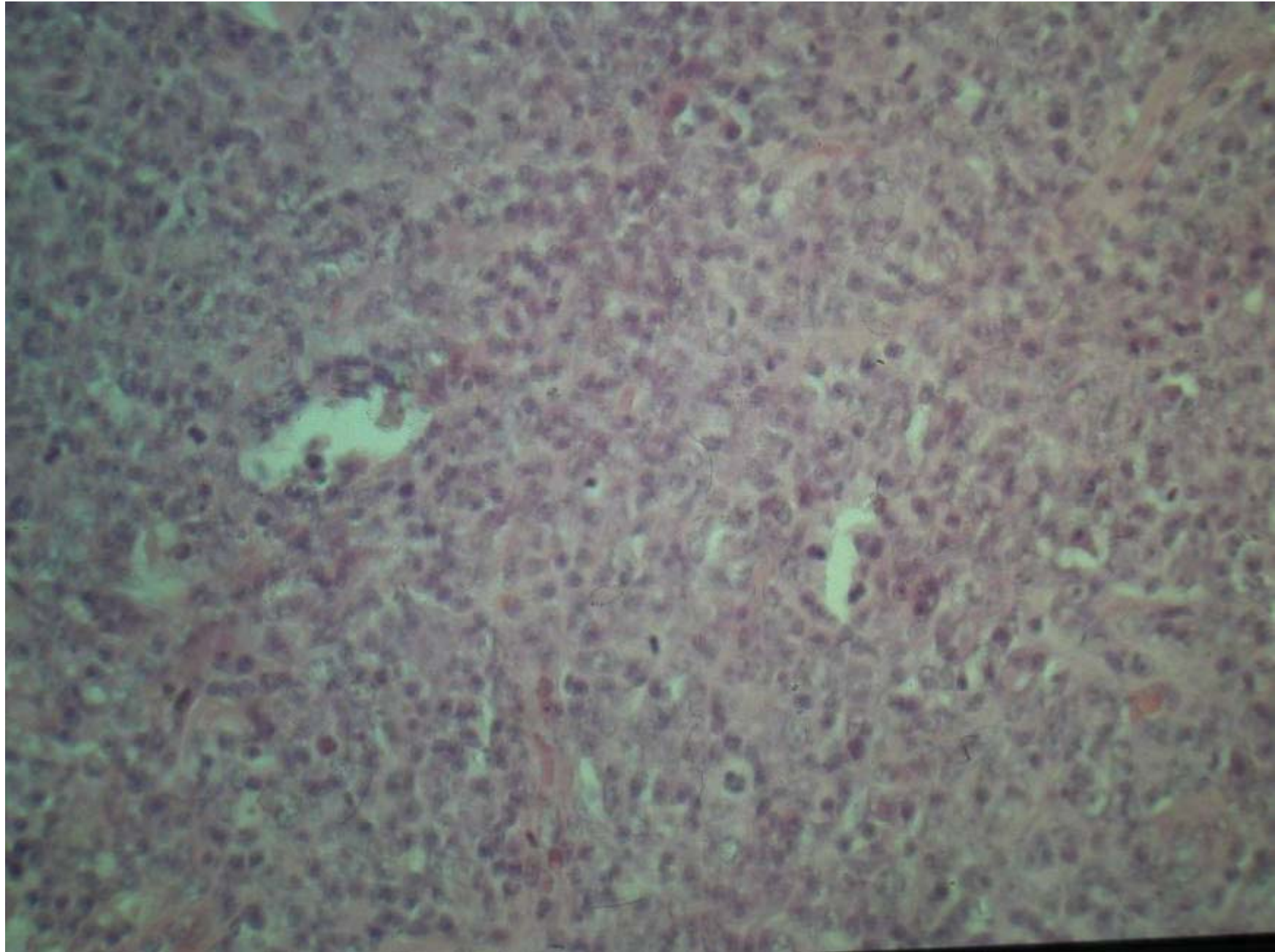
Cutaneous T cell lymphoma



B-cell lymphomas

B-cell lymphoma

B-cell lymphoma



Lymphoma classification

CLASSIFICATION FOR PRIMARY CUTANEOUS LYMPHOMAS

Table 1. EORTC Classification for Primary Cutaneous Lymphomas

Primary CBCL	
Indolent	Follicle center cell lymphoma
	Immunocytoma (marginal zone B-cell lymphoma)
Intermediate	Large B-cell lymphoma of the leg
Provisional	Intravascular large B-cell lymphoma
	Plasmacytoma

Abbreviations: CTCL, cutaneous T-cell lymphoma; CBCL, cutaneous B-cell lymphoma; MF, mycosis fungoides; SS, Sezary syndrome.

Follicle center- cell lymphoma

Follicle center-cell lymphoma

Follicle center-cell lymphoma



Follicle center-cell lymphoma



Large B-cell lymphoma

Pseudolymphomas

CLINICOPATHOLOGICAL SUBTYPE	PREDOMINANT LYMPHOID SUBSET	PREDOMINANT LOCALIZATION	MAJOR ASSOCIATED FINDINGS
Cutaneous lymphoid hyperplasia	B or T cell	Reticular dermis	—
Kimura's disease	B cell	Reticular dermis/subcutis	Lymphadenopathy, eosinophilia
Castleman's disease	B cell	Subcutis	Lymphadenopathy, POEMS syndrome
Pseudo-mycosis fungoides	T cell	Papillary dermis/epidermis	—
Follicular mucinosis	T cell	Hair follicle/perifollicular dermis	Alopecia
Lymphomatoid contact dermatitis	T cell	Papillary dermis/epidermis	Contact allergen
Actinic reticuloid	T cell	Dermis/epidermis	Photosensitivity, lymphadenopathy, circulating atypical lymphocytes
Lymphomatoid papulosis	T cell	Dermis/epidermis	Lymphoma
Angioimmunoblastic lymphadenopathy	T cell	Dermis	Lymphadenopathy, hepatosplenomegaly dysproteinemia, anemia, lymphoma
Lymphomatoid granulomatosis	T cell	Reticular dermis/subcutis	Pulmonary lesions, lymphoma
Lymphocytic infiltration of the skin	T cell	Perivascular/periadnexal dermis	—

Lymphomatoid papulosis