

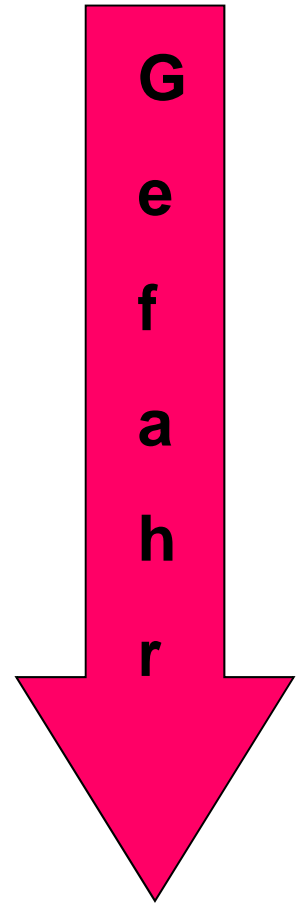


Epitheliale Hauttumoren, gutartige Hauttumoren

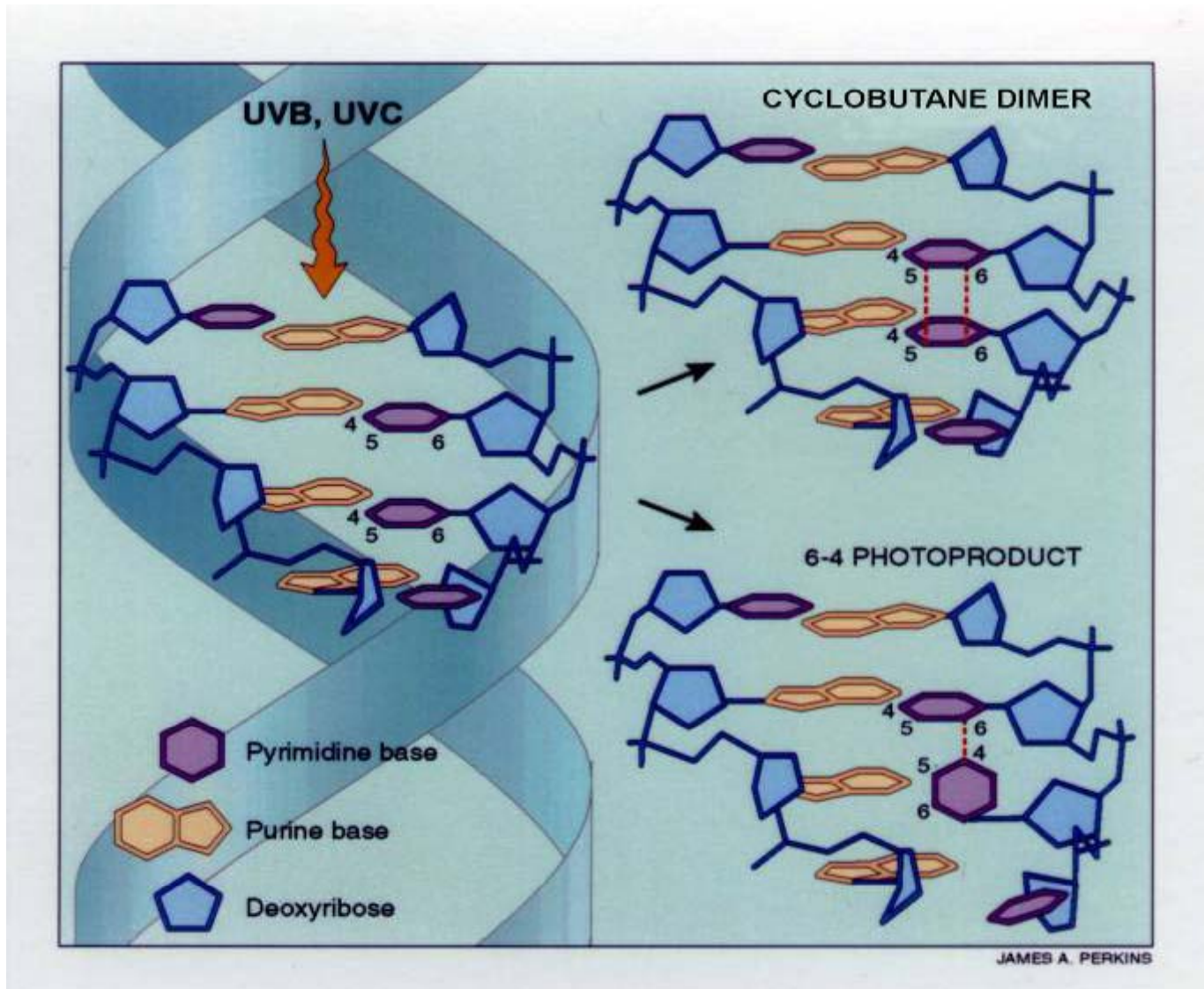
**Basalzellen Karzinom, Plattenepithel Karzinom,
Kaposi Sarkom, Kutane Lymphomen**

Krankheitsbilder

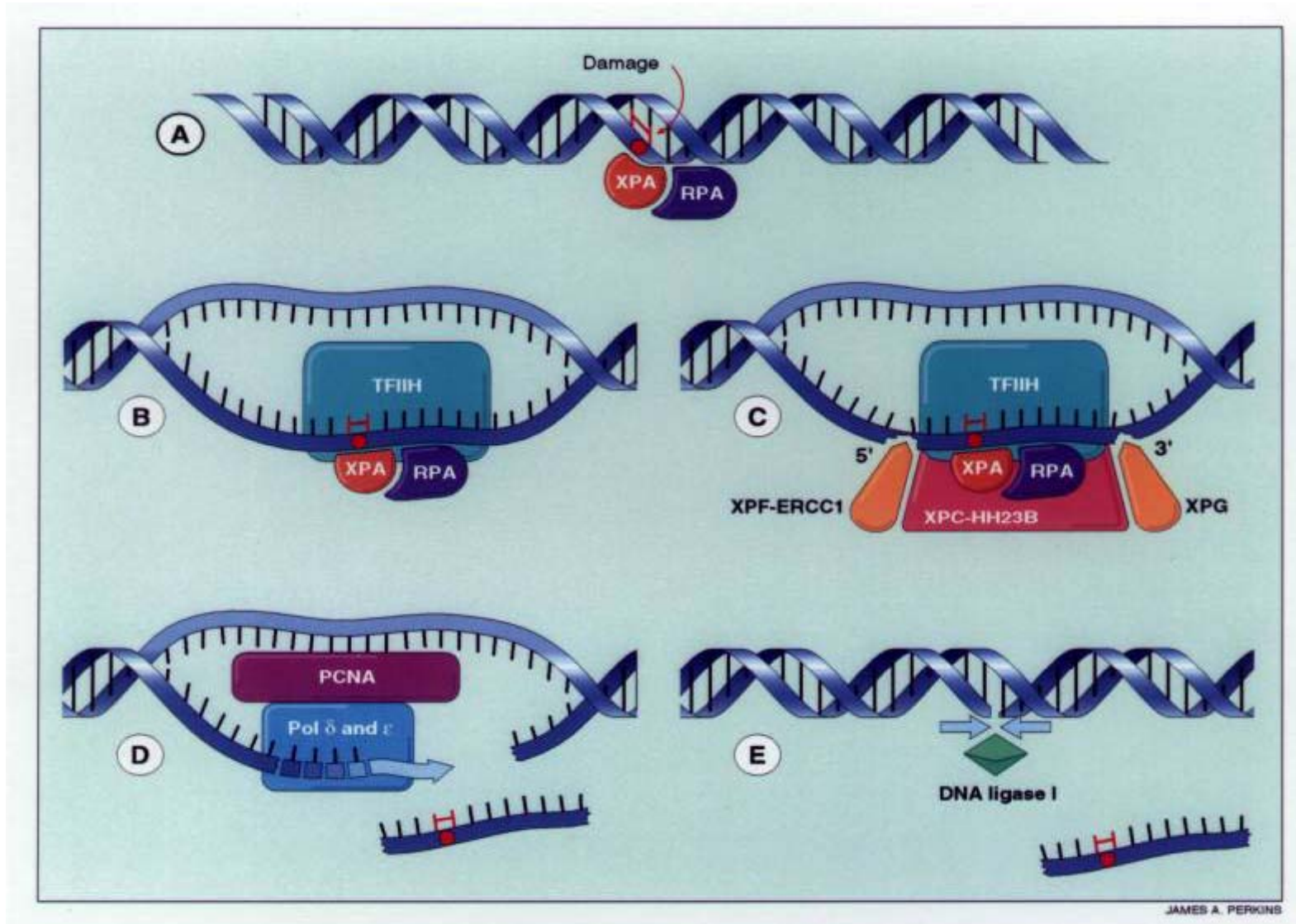
1. Basalzellen Karzinom
2. Plattenepithel Karzinom = Spinocelluläres Karzinom
3. Melanoma malignum



UV Fotoprodukte

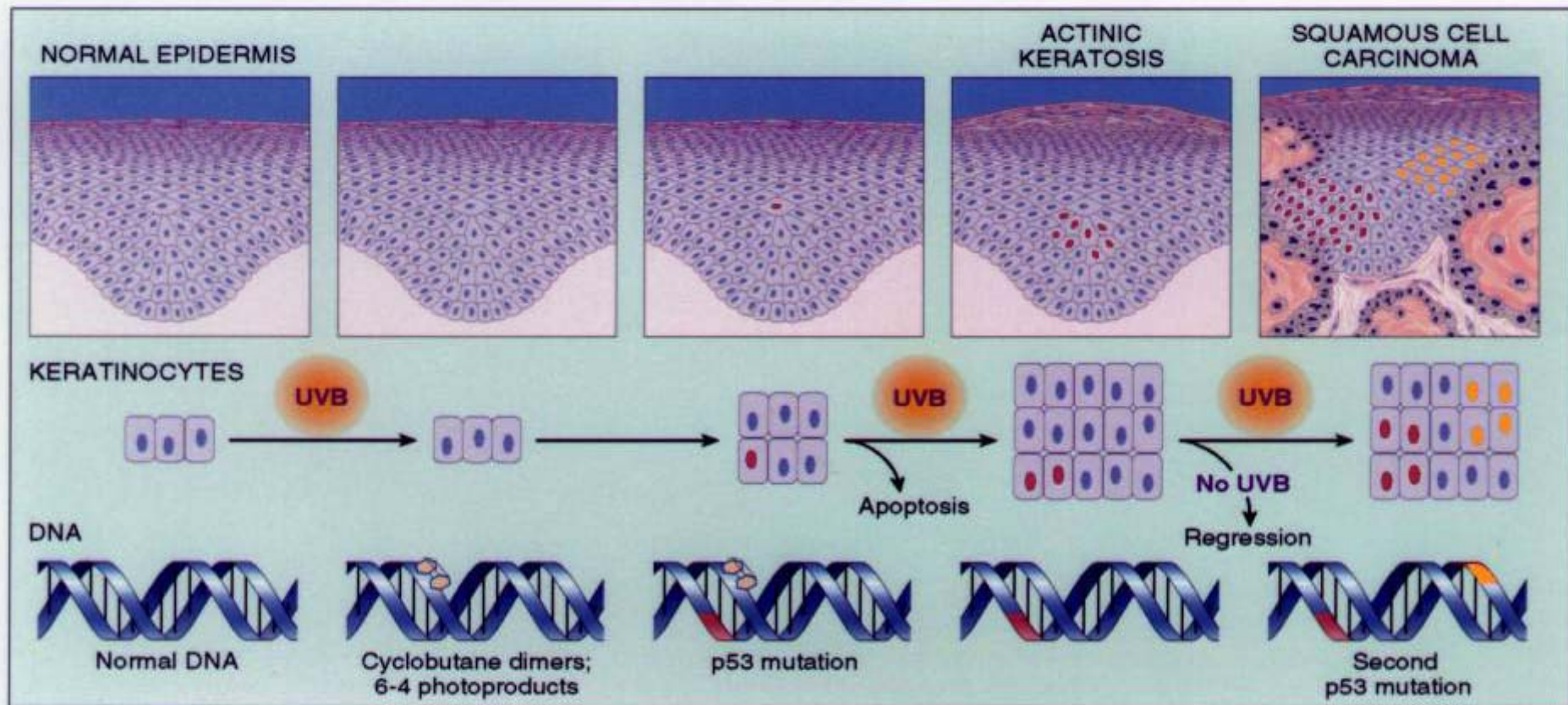


Excision Reperatur-Fehler



Xeroderma pigmentosum

Klonale Ausbildung von Non-melanoma Hauttumoren



JAMES A. PERKINS

Basalzellen Karzinom

Basalzellen Karzinom -Klinische Erscheinung

- Solider
- Nodulärer
- Exulcerans
 - Ulcus Rodens
- Sclerotisierender – Morphe-like
- Pigmentierter
- Cystischer
- Superfizieller

Basalzellen Karzinom

Basalzellen Karzinom

Basalzellen Karzinom

Superfizieller Basaliom

Morphea-like Basalzellen Karzinom

Basalzellen Karzinom in jungen Alter

Basaliom

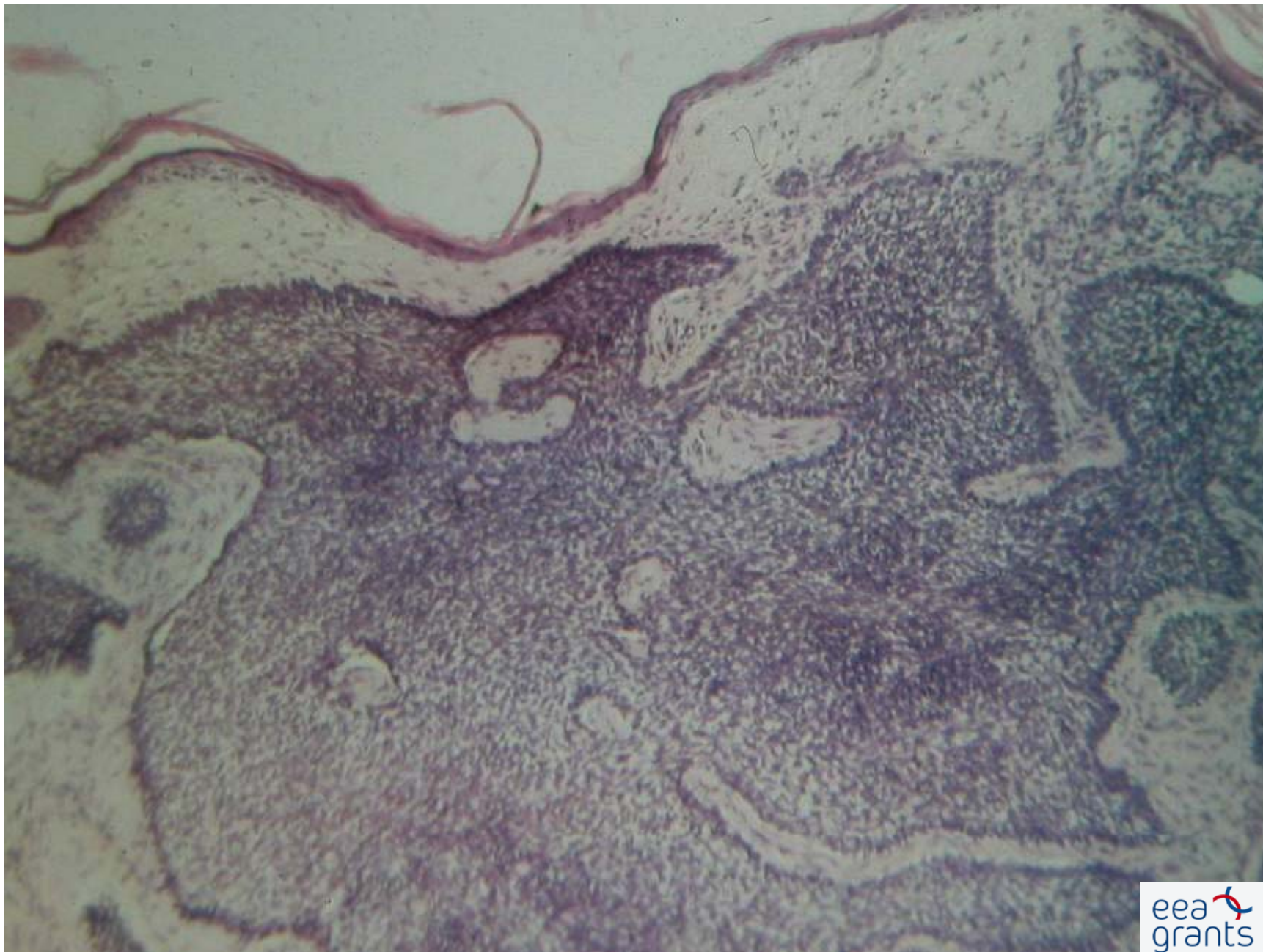
Basalzellen Karzinom

Basalzellen Karzinom -pigmentierter

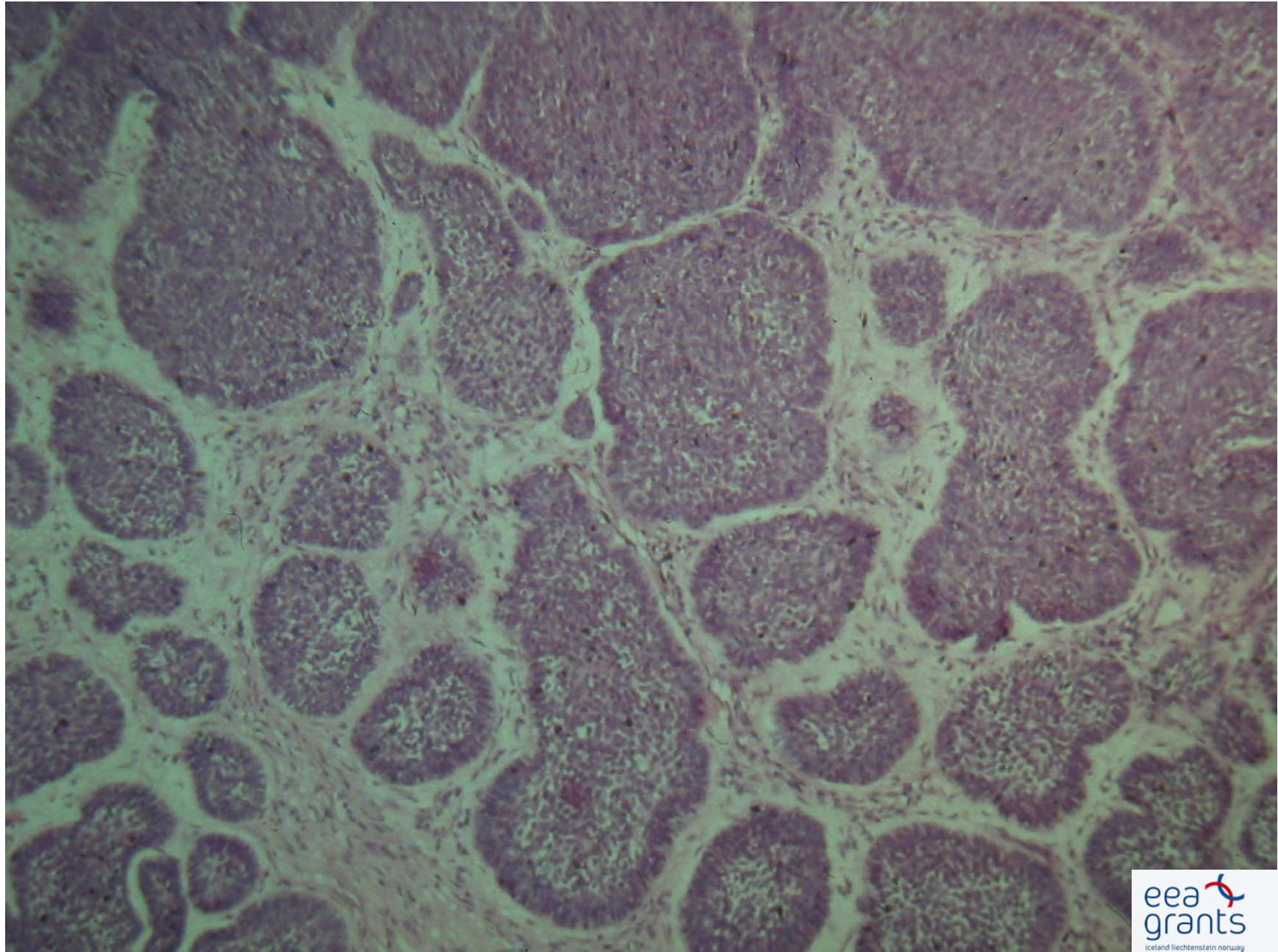
Pigmentierter Basaliom

Ulcus Rodens

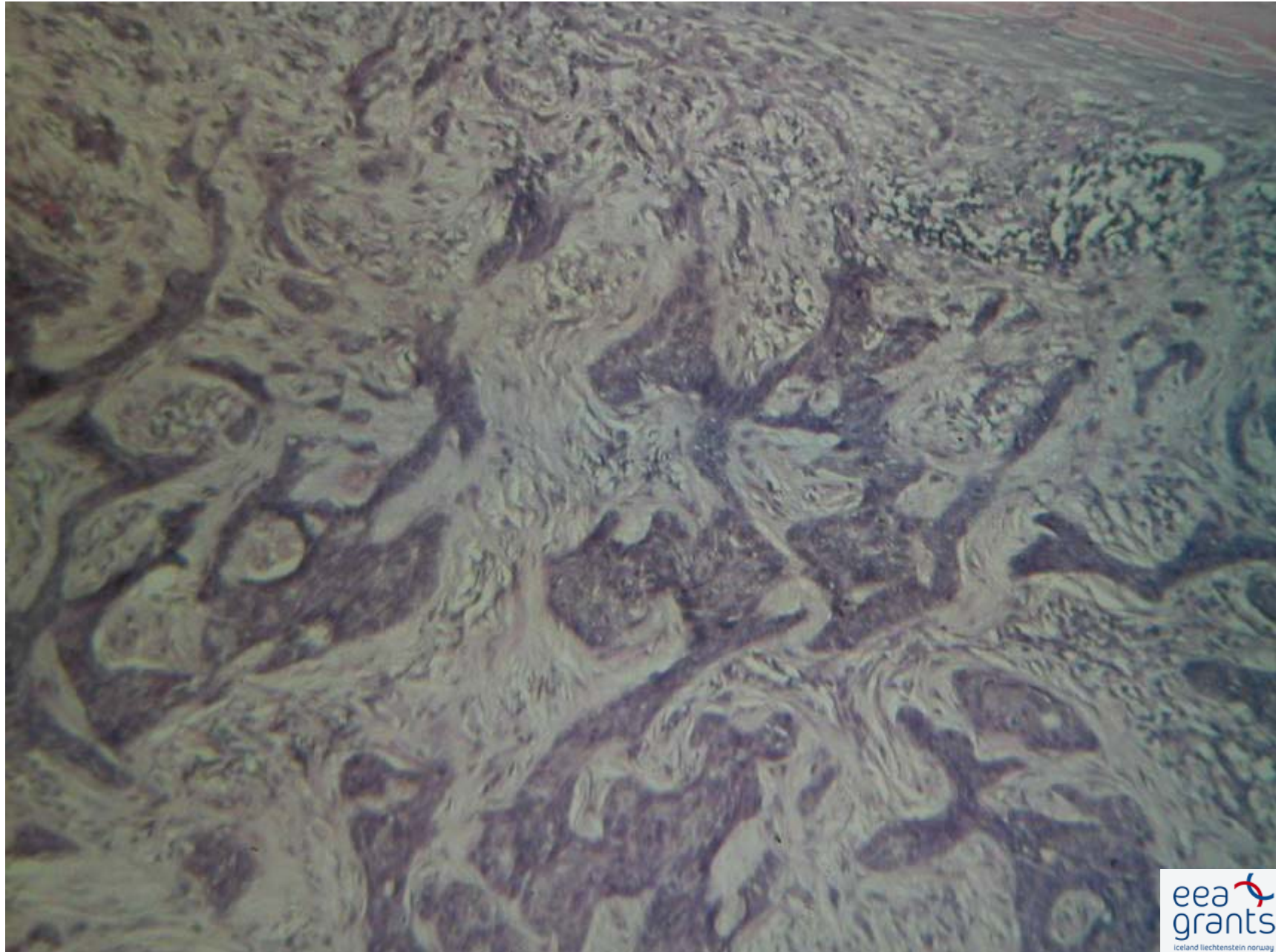
Solide Basaliom



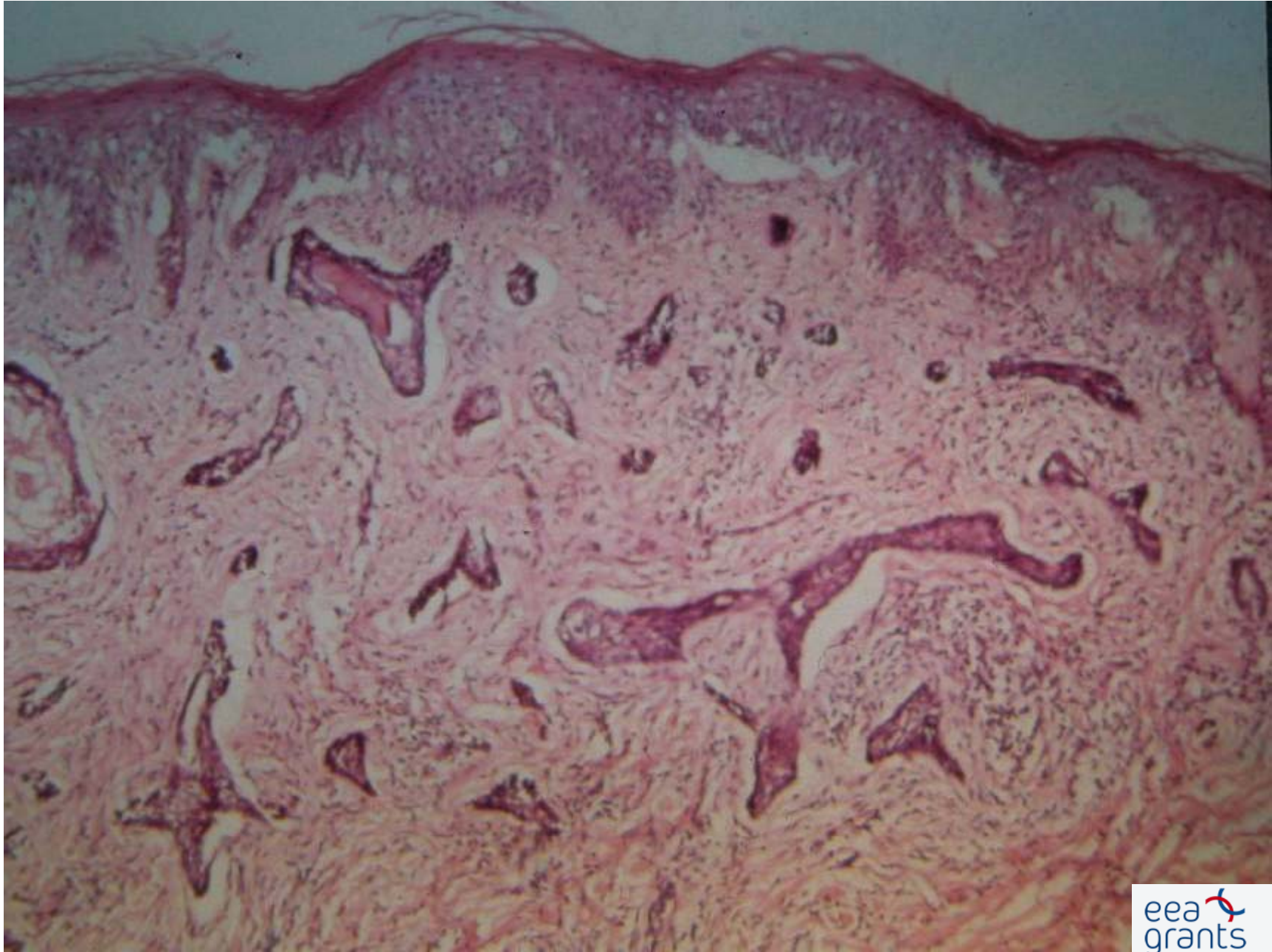
Mikronoduläre Basaliom



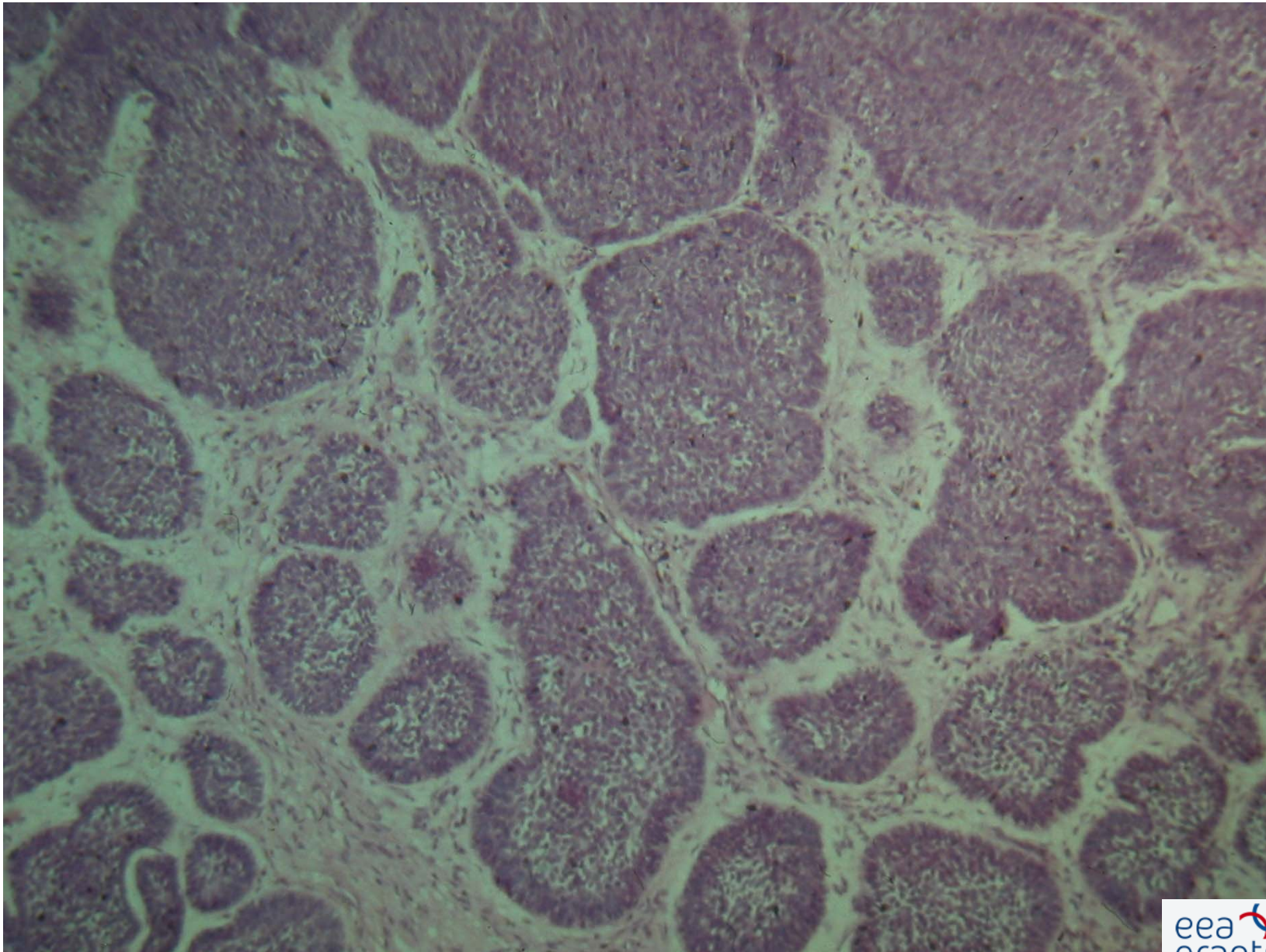
Infiltrative Basaliom



Morphea-like Basaliom



Adenoide Basaliom



Therapie

Primer: chirurgisch!

Irradiation

MOHS surgery

Cryotherapie

Electrodesiccatio und curettage

Photodynamische Behandlung

Chemosurgery

Carcinoma Spinocellulare

Carcinoma Spinocellulare

Carcinoma Spinocellulare

Carcinoma Spinocellulare

Carcinoma Spinocellulare

Spinozelluläres Karzinom

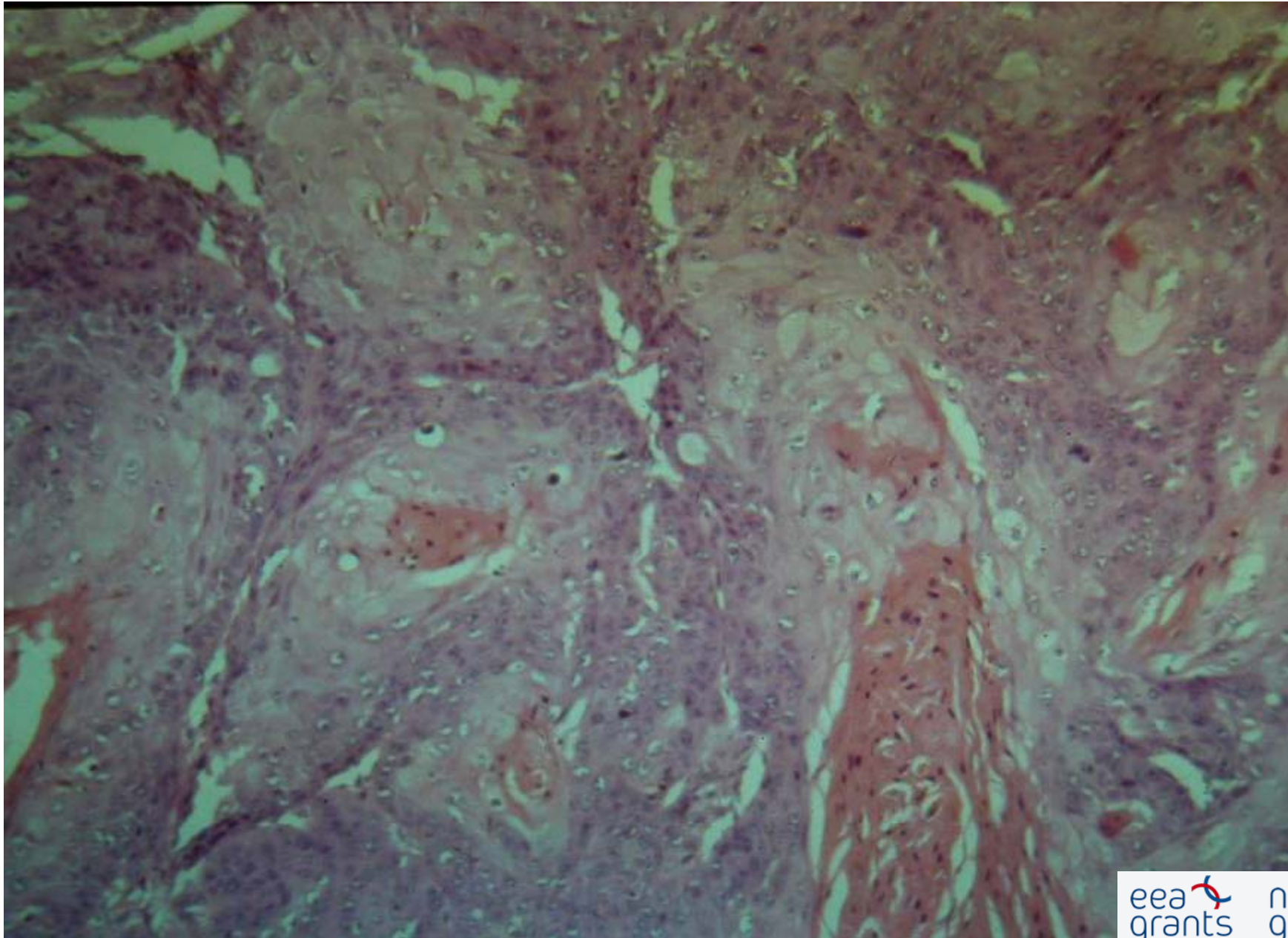
Spinozelluläres Karzinom

Spinocelluläres Karzinom am Lippen

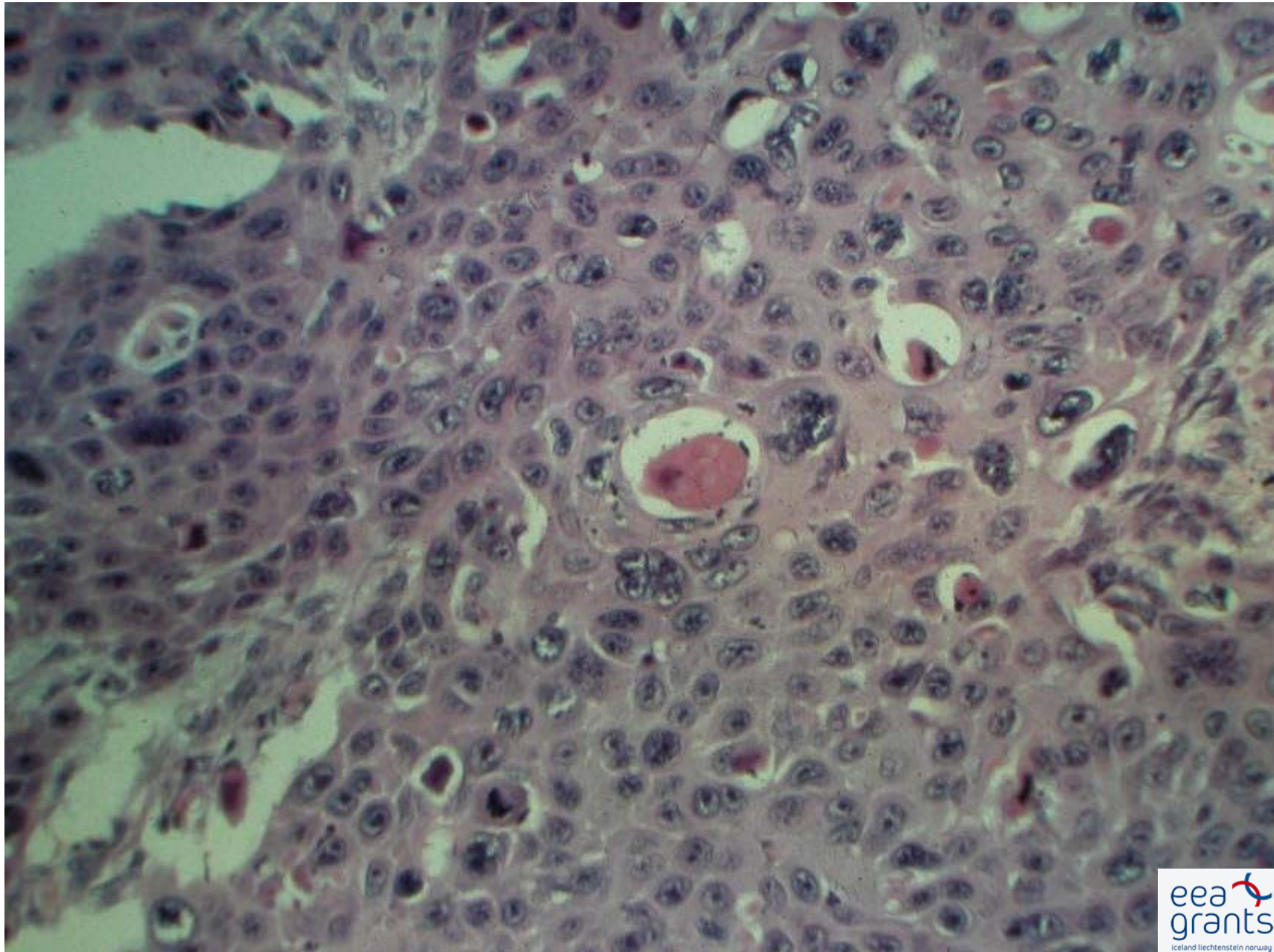
Spinozelluläres Karzinom

Spinozelluläres Karzinom

Spinozelluläres Karzinom



Spinozelluläres Karzinom



Terapie

Chirurgisch!

Praecancerosen

1. Basaliom = keine
2. Spinaliom = Aktinische Keratose

Chronische Lichtexposition

Aktinische Keratose

Morbus Bowen

Keratoacathom

Therapie

Chirurgisch

Irradiation

MOHS surgery

Cryotherapie

Electrodesiccation und curettage

Photodynamische Behandlung

Kaposi Sarkom

1. Klassische
2. AIDS – Assoziierte
3. Endemische
4. Iatrogen

Kaposi Sarkom

Kaposi Sarkom

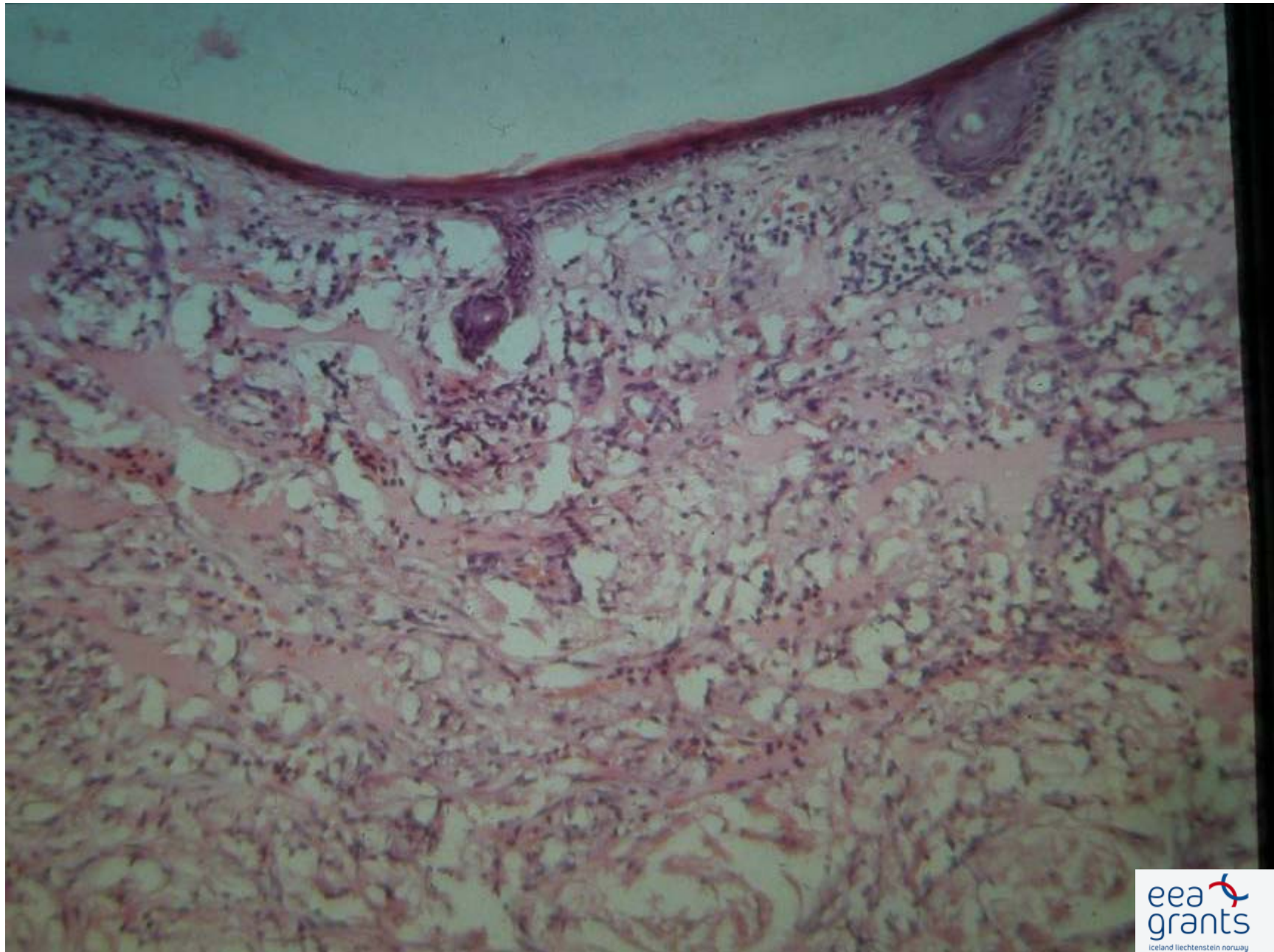
Kaposi Sarkom

Kaposi Sarkom

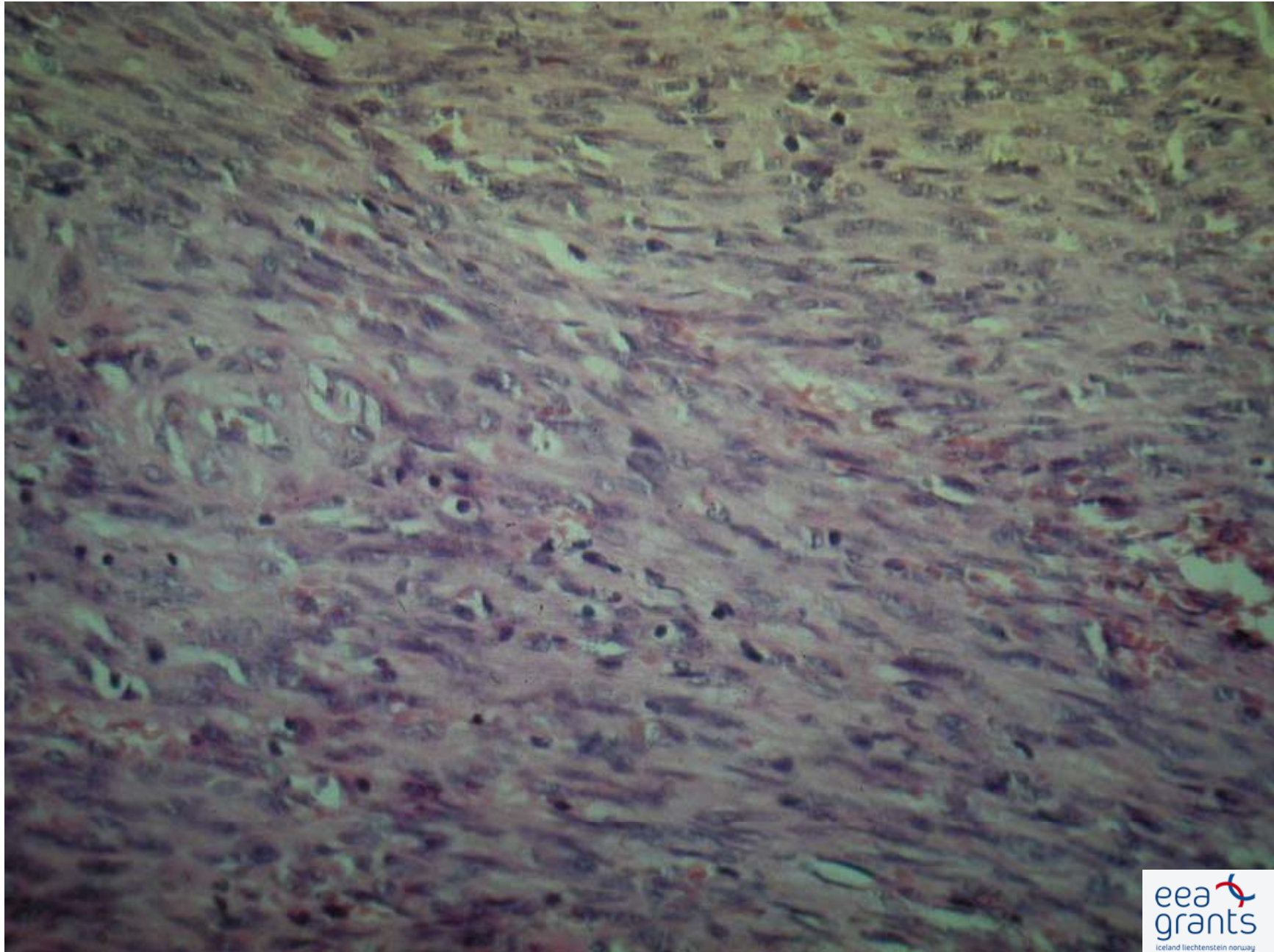
Kaposi Sarkom

Endemisches Kaposi Sarkom

Kaposi Sarkom- histologisches Bild



Kaposi Sarkom- histologisches Bild



Therapie

Lokale Irradiation
Kryotherapie
Laser Koagulation

Interferon alfa-2a
Cytostatischer Therapie

Seborrhoische Keratose

Seborrhoische Keratose

Seborrhoische Keratose

Seborrhoische Keratose

Seborrhoische Keratose

Lymphomen

Lymphomen Klassifikation

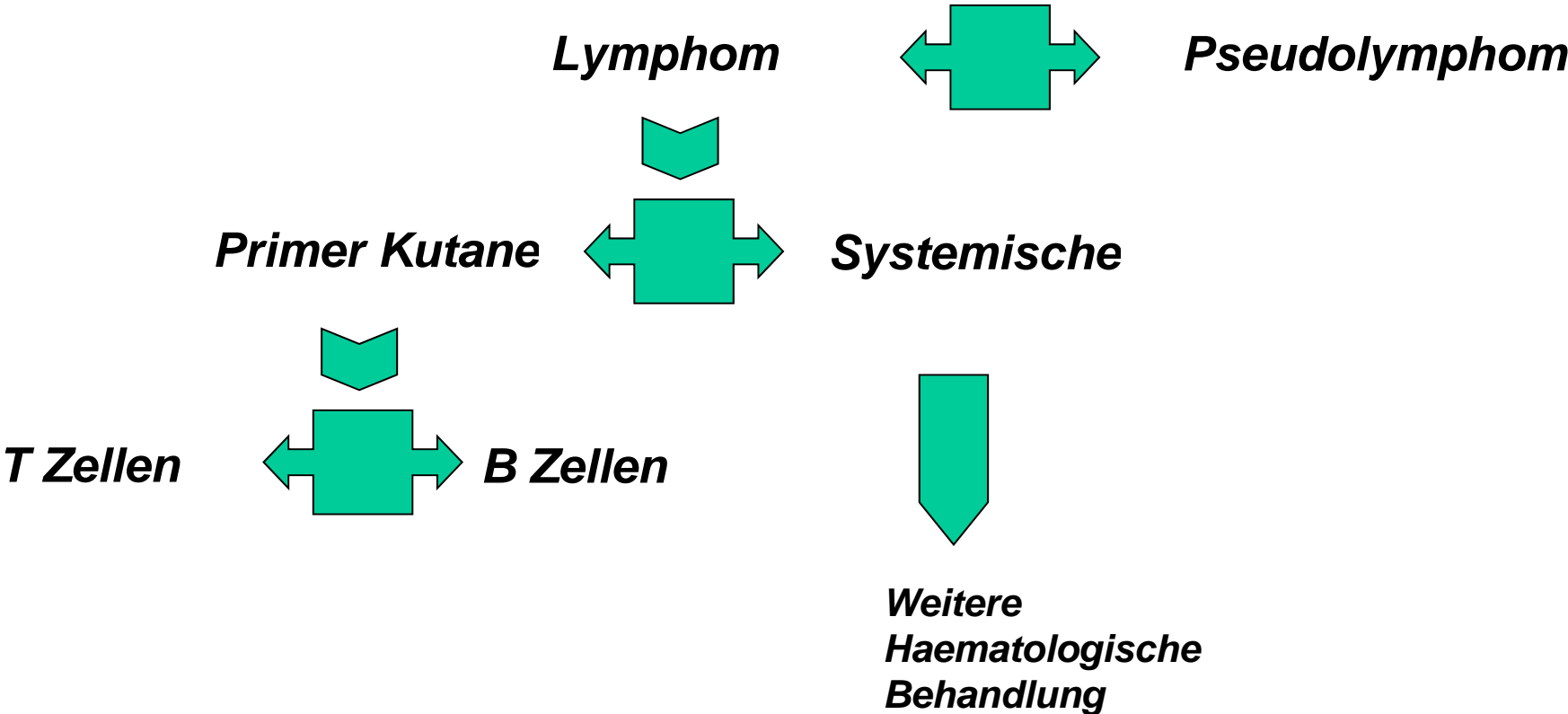
CLASSIFICATION FOR PRIMARY CUTANEOUS LYMPHOMAS

Table 1. EORTC Classification for Primary Cutaneous Lymphomas

Primary CTCL	Primary CBCL
Indolent	Indolent
MF	Follicle center cell lymphoma
MF + follicular mucinosis	
Pagetoid reticulosis	Immunocytoma (marginal zone B-cell lymphoma)
Large cell CTCL, CD30 ⁺	
Anaplastic,	
Immunoblastic	
Pleomorphic	Intermediate
Lymphomatoid papulosis	Large B-cell lymphoma of the leg
Aggressive	
SS	
Large cell CTCL, CD30 ⁻	
Immunoblastic,	
Pleomorphic	
Provisional	Provisional
Granulomatous slack skin	Intravascular large B-cell lymphoma
	Plasmacytoma
CTCL, pleomorphic small/medium-sized	
Subcutaneous panniculitis-like T-cell lymphoma	

Abbreviations: CTCL, cutaneous T-cell lymphoma; CBCL, cutaneous B-cell lymphoma; MF, mycosis fungoides; SS, Sezary syndrome.

Differentialdiagnostische Leitlinien für Lymphomen



Kutane Lymphomen - Staging

• ***Klinisches Bild***

• ***Hystologie***

• ***Immunhystochemie***

• ***Gen Reordnung
Untersuchungen***

***Peripherisches Blut
(Sezary Zellen, flow
cytometrie,
Genreordnung)***

Knochenmark

Lymphknoten

***Innere Organen: Rtg,
USG, CT***

Lymphomen Klassifikation

CLASSIFICATION FOR PRIMARY CUTANEOUS LYMPHOMAS

Table 1. EORTC Classification for Primary Cutaneous Lymphomas

Primary CTCL	
Indolent	
MF	
MF + follicular mucinosis	
Pagetoid reticulosis	
Large cell CTCL, CD30 ⁺	
Anaplastic,	
Immunoblastic	
Pleomorphic	
Lymphomatoid papulosis	
Aggressive	
SS	
Large cell CTCL, CD30 ⁻	
Immunoblastic,	
Pleomorphic	
Provisional	
Granulomatous slack skin	
CTCL, pleomorphic small/ medium-sized	
Subcutaneous panniculitis-like T-cell lymphoma	

Abbreviations: CTCL, cutaneous T-cell lymphoma; CBCL, cutaneous B-cell lymphoma; MF, mycosis fungoides; SS, Sezary syndrome.

Primärer T Zellen Hautlymphom

Mycosis fungoides

- Premykotische Stadium
- Plaque Stadium
- Tumor Stadium

Sézary Syndrom

Mycosis Fungoides -Praemykotische Stadium

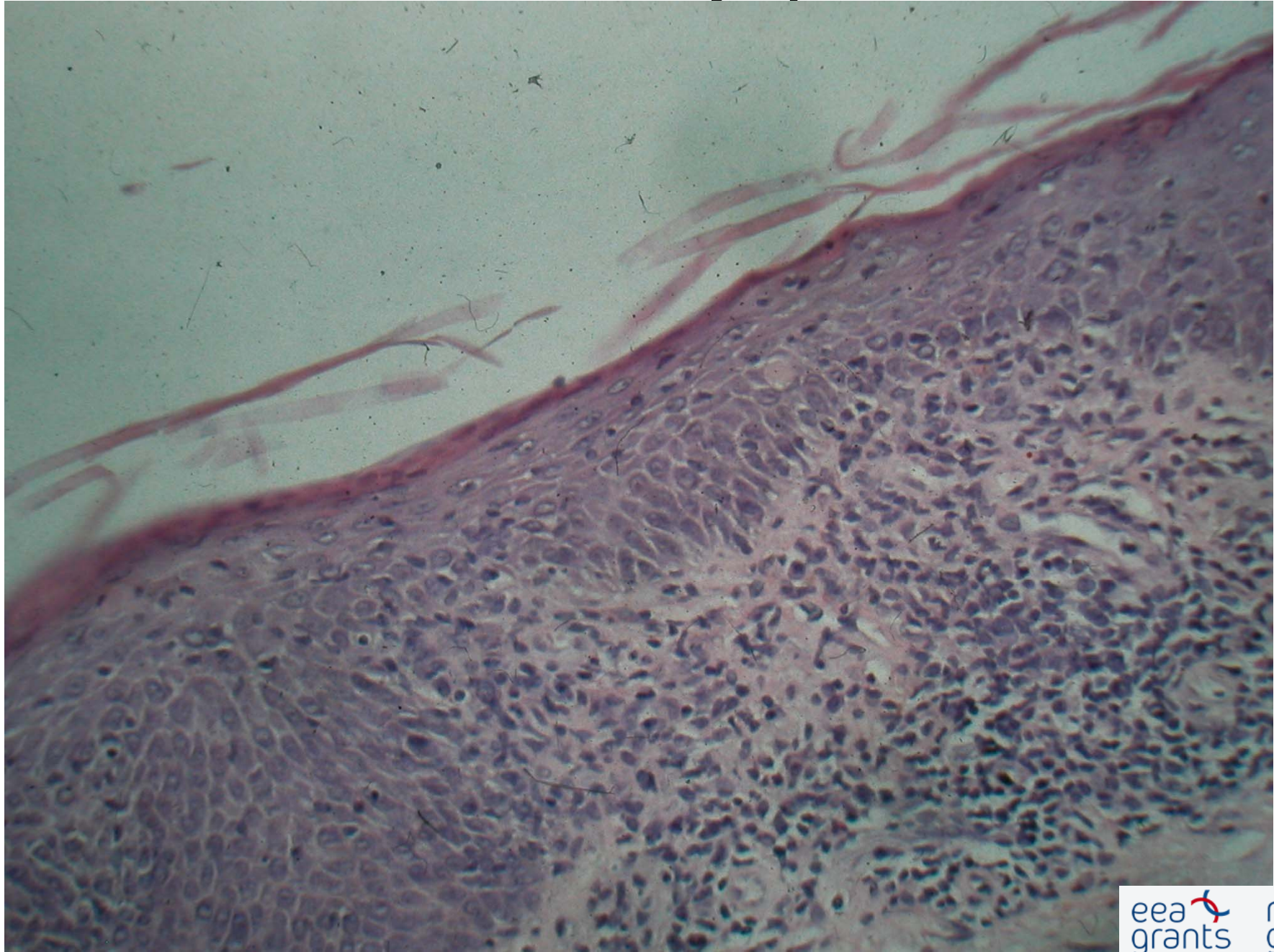
Mycosis Fungoides -Praemykotische Stadium

MF -Plaque Stadium

Sezary Syndrom

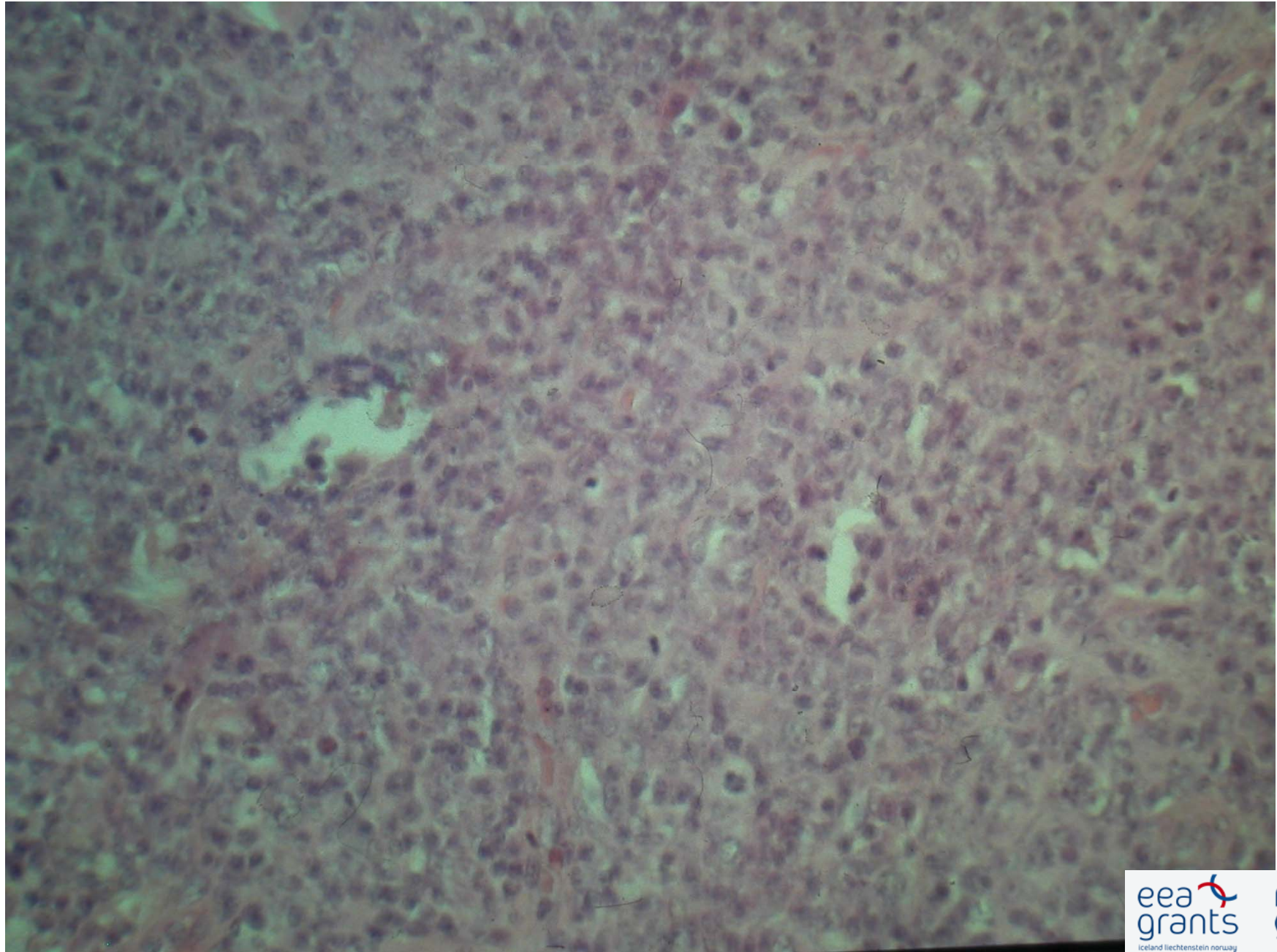
Sezary Syndrom

Kutane T Zellen Lymphom



B-Zellen Lymphomen

B-Zellen Lymphom



Follikel Zenter-Zellen Lymphom

Follikel Zenter-Zellen Lymphom

Follikel Zenter-Zellen Lymphom